



ORIGINAL RESEARCH PAPER

Ophthalmology

KERATIN CYST AN UNUSUAL CAUSE OF EYELID MASS

KEY WORDS: keratin cyst, benign tumor, stratified squamous epithelium, Multilocular cyst, Chalazion, Epidermal tissue.

Dr. Rahul Krishnamurthy*	Junior Resident, Department of Ophthalmology, D Y Patil Medical College, Kadamwadi Kolhapur. *Corresponding Author
Dr. Gayatri Rajendra Gondhali	Junior Resident, Department of Ophthalmology, D Y Patil Medical College, Kadamwadi Kolhapur.
Dr Milind M Sabnis	Professor and HOD Department of Ophthalmology, D Y Patil Medical College, Kadamwadi Kolhapur

ABSTRACT

Introduction: Keratin cysts are benign, keratin-filled lesions lined by epidermal tissue. These slow-growing tumors result from the proliferation of epidermal cells within the dermis. Although typically asymptomatic, they are most commonly located on the scalp, face, neck, chest, back, and extremities. [1] **Case Report:** We report the case of a 53-year-old male who presented with a painless swelling on his right upper eyelid, which had persisted for eight years but had shown significant growth over the past year. On examination, the swelling was non-tender, with no local rise in temperature, pulsations, or bruits. The patient underwent surgical excision of the lesion. Histopathological analysis revealed tissue lined by stratified squamous epithelium with multilocular cysts filled with keratin, confirming the diagnosis of a keratinous cyst. **Conclusion:** Although rare, keratin cysts can manifest as eyelid masses and may be misdiagnosed as chalazion. Incision and curettage (I&C) are often ineffective, leading to recurrence of the cyst. Complete surgical excision with the intact capsule is the treatment of choice, as it significantly reduces the likelihood of recurrence. This case highlights the importance of considering keratin cysts in the differential diagnosis of eyelid masses and underscores the necessity of histopathological evaluation for accurate diagnosis and appropriate management.

INTRODUCTION

Keratin cysts, also known as epidermoid cysts, are benign lesions filled with keratin and lined by epidermal tissue. These cysts are slow-growing tumors that originate from the proliferation of epidermal cells within the dermis. Although they are typically asymptomatic, they can sometimes cause discomfort or become cosmetically concerning for the patient. Keratin cysts are commonly found on the scalp, face, neck, chest, back, and extremities but are rarely reported in the periorbital region, making this case noteworthy. [2-4]

The eyelid is an uncommon site for keratin cysts, and their presentation can often mimic more common eyelid lesions such as chalazion. This can lead to misdiagnosis and inappropriate treatment, which may not effectively resolve the cyst and could result in recurrence. Therefore, it is crucial for clinicians to consider keratin cysts in the differential diagnosis of eyelid masses and to utilize histopathological evaluation to ensure accurate diagnosis and management. [5,6]

Case Report

A 53-year-old male presented to our clinic with a chief complaint of a painless swelling on his right upper eyelid. The patient reported that the swelling had been present for eight years but had notably increased in size over the past year. The swelling was described as non-tender and had not caused any significant discomfort or visual impairment. The patient had no history of trauma or previous surgery in the area.

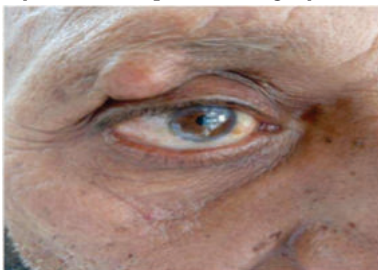

Fig 1 Showing Right Eye Upper Lid Mass

On physical examination, the swelling was localized to the right upper eyelid. It was non-tender, with no local rise in temperature, pulsations, or bruits. The lesion was firm and well-circumscribed, measuring approximately 1.5 cm in diameter. There were no signs of inflammation or infection. The remainder of the ocular examination was unremarkable, with no evidence of conjunctival injection or discharge.

Given the clinical presentation, a provisional diagnosis of chalazion was considered. However, due to the unusual duration and recent growth of the lesion, further investigation was warranted. The patient consented to surgical excision of the mass for definitive diagnosis and treatment.

The surgical procedure was performed under local anesthesia. A small incision was made over the lesion, and the cyst was meticulously dissected from the surrounding tissues. The cyst was excised in its entirety, including the intact capsule, to minimize the risk of recurrence. The excised tissue was sent for histopathological examination.

Histopathological analysis revealed a cystic structure lined by stratified squamous epithelium. The cyst was multilocular and filled with keratinous material, consistent with a diagnosis of a keratinous cyst. There were no signs of malignancy or other pathological features.

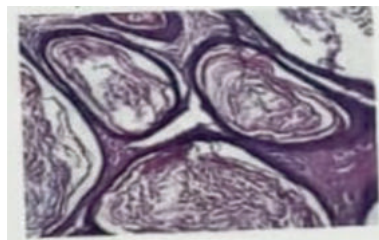


Fig 2 Histopathology Slide Showing Keratin Cysts.

DISCUSSION

Keratin cysts are common benign lesions, but their

occurrence in the eyelid is rare. These cysts arise from the proliferation of surface epidermal cells that become trapped within the dermis. Over time, these cells produce keratin, leading to the formation of a cystic structure filled with keratinous material.^[2] The etiology of keratin cysts is not fully understood, but they are thought to result from developmental anomalies, trauma, or inflammatory processes^[7]

The differential diagnosis for an eyelid mass includes chalazion, sebaceous cyst, dermoid cyst, and other benign or malignant lesions. Chalazion is a common eyelid lesion caused by the blockage and inflammation of a meibomian gland. It typically presents as a painless, non-tender swelling on the eyelid and can be treated with conservative measures such as warm compresses and incision and curettage (I&C). However, recurrent or atypical cases should prompt further investigation to rule out other potential diagnoses.^[8-10]

In this case, the patient's long-standing history of the lesion and its recent growth necessitated surgical excision and histopathological evaluation. Histopathology is the gold standard for diagnosing keratin cysts, as it provides definitive evidence of the cyst's epithelial lining and keratin content.^[11] The presence of stratified squamous epithelium and keratinous material within the cyst confirms the diagnosis of a keratinous cyst.

Surgical excision with intact capsule removal is the treatment of choice for keratin cysts. This approach minimizes the risk of recurrence, which is higher with I&C due to the potential for incomplete removal of the cyst wall. Complete excision ensures that all epithelial components are removed, reducing the likelihood of cyst reformation.^[12]

The prognosis for patients with keratin cysts is excellent following complete surgical excision. Recurrence is rare when the cyst is entirely removed, and complications are minimal. Patients should be advised to monitor for any signs of recurrence and seek prompt medical attention if they notice any changes.^[13]

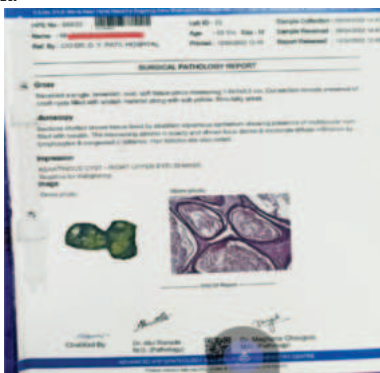CONCLUSION

Keratin cysts, although benign and typically asymptomatic, can present as unusual masses in uncommon locations such as the eyelid. Their presentation can mimic more common eyelid lesions like chalazion, leading to potential misdiagnosis and inappropriate treatment. This case underscores the importance of considering keratin cysts in the differential diagnosis of eyelid masses and highlights the necessity of histopathological evaluation for accurate diagnosis and effective management.^[14,15]

Complete surgical excision with the intact capsule is the preferred treatment for keratin cysts, as it significantly reduces the risk of recurrence. Clinicians should maintain a high index of suspicion for keratin cysts in patients presenting with persistent or atypical eyelid masses and ensure that appropriate diagnostic and therapeutic measures are undertaken.^[16]

REFERENCES

1. Alsaad KO, Obaidat NA, Ghazarian D. Skin adnexal neoplasms—part 1: an approach to tumours of the pilosebaceous unit. *J Clin Pathol.* 2007;60(2):129-144.
2. Elder DE, Elenitsas R, Johnson BL Jr, Murphy GF. *Lever's Histopathology of the Skin.* 10th ed. Lippincott Williams & Wilkins; 2008.
3. McGregor, J. C., & Brooke, R. C. (2010). Benign Tumors of the Skin. In *Dermatology* (pp.1534-1541). Saunders Elsevier.
4. Moore, M., & Shell, B. (2018). Epidermoid and Pilar Cysts. In *Surgical Dermatology: A Practical Guide for Beginners* (pp. 117-122). Springer.
5. Lin, K., & Patel, B. C. (2019). Periorbital Epidermoid Cysts: A Case Series and Literature Review. *Journal of Ophthalmic Inflammation and Infection*,9(1), 1-7. doi:10.1186/s12348-019-0198-0
6. Vandervort, J. G., & Hornblass, A. (1990). Epidermoid Cysts of the Eyelid. *Ophthalmology*,97(11), 1525-1528. doi:10.1016/S0161-6420(90)32454-8
7. Sánchez Yus E, Simón P, Requena L, Ambrojo P, Valbuena M. Pilar (trichilemmal) cyst: a clinicopathologic study of 33 cases. *Int J Dermatol.* 1992;31(10):791-796.
8. Weedon D. *Weedon's Skin Pathology.* 3rd ed. Churchill Livingstone Elsevier; 2010.
9. Yanguas JI, Díaz-Cascajo C, Borghi S, Barnadas MA. Multiple trichilemmal cysts with focal calcification. *Clin Exp Dermatol.* 1999;24(5):401-403.
10. Goldstein, B.C., Goldstein, A. O. (2019). Epidermoid cysts. In: Wolff K., Johnson R.A., Saavedra A.P., Roh E.K. (Eds.), *Fitzpatrick's Color Atlas and Synopsis of Clinical Dermatology.* 8th edition. McGraw-Hill Education.
11. Gritz DC, Wong IG. Incision and curettage of chalazias. *Survey of Ophthalmology.* 2004;49(4):328-334.
12. Sethi, A., Sareen, D., Sethi, D., & Bansal, P. (2011). Histopathological spectrum of eyelid lesions: A study of 162 cases. *International Journal of Ophthalmology*, 4(6), 634-638.
13. Gonzalez, E.A., & Ko, C.J. (2015). Benign epithelial tumors, hamartomas, and hyperplasias. In: Bologna J.L., Schaffer J.V., Cerroni L. (Eds.), *Dermatology.* 4th edition. Elsevier.
14. DeBacker, C.M., & Johnson, P.C. (2008). *Pathology of the Eyelid and Orbit.* In: Yanoff M., Duker J.S. (Eds.), *Ophthalmology.* 4th edition. Elsevier
15. Banik, R., Patel, N., Jain, A., & Mitra, A. (2013). Unusual presentation of epidermoid cyst as a subcutaneous swelling in eyelid. *Journal of Clinical and Diagnostic Research*, 7(7), 1453-1454.
16. Cummings, C.W., Flint, P.W., Haughey, B.H., Robbins, K.T., Thomas, J.R., Harker, L.A., Richardson, M.A., Schuller, D.E. (2004). *Cummings Otolaryngology: Head and Neck Surgery.* 4th edition. Elsevier.



Histopathology Report of the Patient