



ORIGINAL RESEARCH PAPER

Internal Medicine

OBSERVATIONAL STUDY TO CO-RELATE FUNDUS FINDINGS IN PATIENTS WITH CEREBROVASCULAR ACCIDENTS

KEY WORDS:

Cerebrovascular accident, Fundoscopy, Hypertension, Diabetes, Mean arterial pressure

TanuJ Kumar Biswas	Assistant Professor, Department Of General Medicine, Silchar Medical College And Hospital, Silchar
Zakir Hussain Laskar	Assistant Professor , Department Of Ophthalmology, Silchar Medical College And Hospital, Silchar
Kaushik Medhi	Junior Resident , Department Of General Medicine, Silchar Medical College And Hospital, Silchar
Lakshmi S	Junior Resident, Department Of Ophthalmology, Silchar Medical College And Hospital, Silchar
Satakshi Shome Purkayastha	Junior Resident , Department Of General Medicine, Silchar Medical College And Hospital, Silchar

ABSTRACT

Objective: The cerebral vessels and the retinal blood vessels are comparable in terms of anatomy, physiology, and development. Alterations in the cerebral vasculature are probably reflected in changes in the retinal vessels. the retinal vessel pathology serves as an important marker for stratification of patients risk for having or developing Cerebrovascular Accident. Thus the objective of the study is to Consociate the link between the retinal signs and strokes and assess the retinal indicators for the etiology of stroke. **Methods :** In this prospective study 50 patients above 18 years of age with CT scan diagnosed Cerebrovascular accidents attending the Department of Medicine, SMCH, Silchar for treatment from January 2024 to June 2024 were included **Results :** Among 50 patients studied ischemic stroke was 82% and haemorrhagic was 9%, majority are males 56% and females comprised of 44%. The mean age was 63.62± 13.27. majority were in the 6th and 7th decade. CVA patients under dilated fundoscopy having SBP >180mmHg and DBP>110mmHg with grade 3,4 diabetic and hypertensive retinopathy had poor prognosis.

INTRODUCTION

Stroke, also known as a cerebrovascular accident (CVA), is the most common neurological emergency and the second leading cause of death worldwide ¹. Numerous investigations have demonstrated that, even when blood pressure and other vascular risk factors are under control, hypertensive ocular fundoscopic abnormalities (focal retinal arteriolar narrowing, arterio-venous nicking) are unquestionably linked to stroke ². There's growing evidence that small-vessel disease, a systemic vascular condition, can play a significant role in the development of stroke ². Signs of diabetic retinopathy, such as hard exudates and microaneurysms, were also linked to incidence stroke and stroke mortality ³.

The cerebral vessels and the retinal blood vessels are comparable in terms of anatomy, physiology, and development. Similar to the blood-brain barrier, the retina is an outgrowth of the diencephalon and has a blood-retinal barrier ⁴. Similar alterations in the cerebral vasculature are probably reflected in changes in the retinal vessels ⁵. According to histologic investigations, thickenings of the retinal arteries around the optic disc called fibrous or fibro-hyalinoid thickenings reflect intracerebral artery abnormalities and are linked to a higher risk of cerebral infarction and cerebral hemorrhage ⁶. Longer retinal arteriovenous transit time, retinal focal arteriolar narrowing, AV nicking, generalized retinal arteriolar narrowing, and generalized venular widening is linked to lacunar infarction ⁷, as demonstrated by functional tests of the retinal vasculature and confirmed by a CT scan ⁸.

The most widely used scale for grading hypertensive retinopathy is the Keith, Wagener and Barker classification, which grades retinopathy from I to IV based on its severity ⁹. The most widely used scale for measuring diabetic retinopathy is ETDRS Disease Severity Scale ¹⁰. The aim of this observational study is to consociate the link between retinal signs and stroke. We reviewed 4 groups of retinal signs: Hypertensive retinopathy, Diabetic retinopathy, Retinal vein

occlusion, Age related macular degeneration.

Signs of hypertensive retinopathy include hard exudates, cotton-wool patches and retinal haemorrhages . These symptoms are known to be prevalent in persons over 40 years, even in those without a history of diabetes or hypertension, with a prevalence of 7.0% to 11.0%.¹¹ . According to histopathologic investigations, retinal ischemia and the disruption of the blood-retina barrier are associated with small vessel arteriolosclerosis, which is linked to retinopathy ^{12,13} .

There are two types of diabetic retinopathy: proliferative (PDR) and non-proliferative (NPDR). The terms cotton-wool spots, venous beading, microaneurysms, retinal haemorrhages, hard exudates, and intraretinal microvascular anomalies are referred to as NPDR. Neovascularization is a sign of proliferative form progression. The prevalence of diabetic retinopathy for all types of diabetes in adults over 40 was found to be 8.2% for PDR and 40.3% for NPDR ¹⁴.

Retinal vein occlusion (RVO) refers to dilated and tortuous veins and the presence of retinal haemorrhages, cotton wool spots, and macular and optic disc edema. In central RVO, all 4 quadrants have haemorrhages, whereas in branch RVO these lesions localize in one sector corresponding to that branch area. The pathogenesis is unclear but is likely multifactorial, and postulated causes include thrombosis in the venule resulting from compression by an adjacent atherosclerotic arteriole, local alteration to blood flow from unfavourable physiological characteristics or hematologic abnormalities ¹⁵. RVO increases with age and prevalence has been reported to be 0.3% to 1.6% in adults aged 40 years and older ^{16,17}.

A degenerative disorder that affects the macular, or core portion, of the retina is known as age-related macular degeneration, or AMD. Soft drusen, or yellow deposits beneath the retinal pigment epithelium, and changes in retinal pigment (hyper- and hypopigmentation) are the

primary features of early AMD. Atrophic (dry) AMD and neovascular (wet) AMD are the two different types of late AMD. Both hereditary and environmental variables are involved in the etiology. After the age of 70, the prevalence of AMD increased exponentially, according to all the research. 15% of people 65 to 74 years old and 25 % of people 75 years and older had early AMD^{16,17}.

Hence this study was performed to look for fundoscopic changes in patients presenting with Cerebrovascular accident (stroke) confirmed by CT scan and we try to assess any correlation between them.

METHODS

Study Design And Patient Population

In this prospective observational study 50 patients above 18 years of age with CT scan diagnosed Cerebrovascular accidents attending the Department of Medicine, SMCH, Silchar for treatment from January 2024 to June 2024 were included randomly.

Inclusion criteria : 1) Patients equal to or above 18 years of age of both sexes 2) CT scan diagnosed cases of spontaneous cerebrovascular accident 3) Fundus is visible either with Direct or Indirect Ophthalmoscope.

Exclusion criteria : 1) Head injury 2) Small vessel ischemic changes 3) Central nervous system infection pertaining to cerebrovascular accident.

Data Collection

All the patients fulfilling the inclusion and exclusion criteria were explained about the purpose of the study. A written informed consent is obtained from the patients/legal guardian. A detailed history and physical examination is done in all patients as per a pre-determined proforma. Clinical parameters at the time of admission like blood pressure , capillary blood glucose were taken into consideration. Dilated funduscopy was done with the help of Direct and Indirect Ophthalmoscope. Dilation of eyes was done with the eye drops containing Tropicamide (0.8%) + Phenylephrine (5%). Routine laboratory investigations including Complete blood count, RBS, serum Lipid profile, serum sodium, serum creatinine, HBA1c and radiological like CT scan were used to find out the correlation.

RESULTS

Among the 50 cases of Cerebrovascular accidents studied Ischemic stroke was 41 (82%) and haemorrhagic stroke was 9 (18%), there were 28 (56%) males and 22 (44%) females. The majority of the patients belonged to 6th and 7th decades (30%). The overall mean age of the study group was 63.62 ± 13.27.

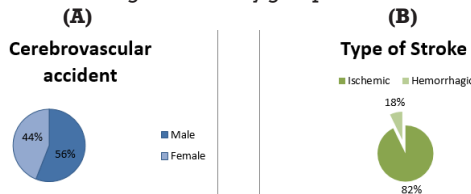


Figure 1 : A) Gender Distribution Among Stroke Patient B) Type Of Stroke

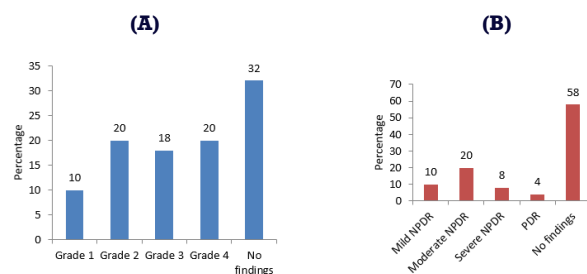


Figure 2 : Fundoscopic Changes In A) Hypertensive Retinopathy B) Diabetic Retinopathy

Grade 1 hypertensive retinopathy was 5 (10%), Grade 2 hypertensive retinopathy was found in 10 (20%), Grade 3 hypertensive retinopathy was found in 9 (15%), Grade 4 hypertensive retinopathy was found in 10 (20%) whereas no signs of hypertensive retinopathy was seen in 16 (31%). Among the diabetics moderate NPDR was highest 10 (20%), mild NPDR in 5 (10%), severe NPDR was found in 4 (8%) whereas signs of PDR was found in 2 (4%). No signs of diabetic retinopathy was seen in 29 (58%).

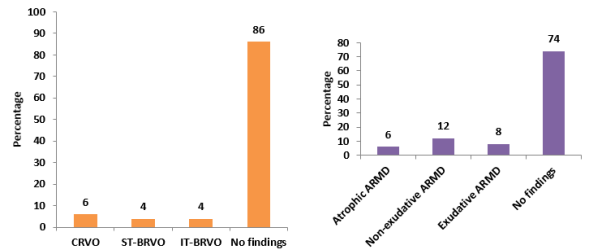


Figure 3 : Fundoscopic Findings Of Retinal Vein Occlusion (rvo) And Age Related Macular Degeneration (arnd) In Cerebrovascular Accidents

Central retinal vein occlusion was seen in 3 (6%), superior-temporal Branched retinal vein occlusion was seen in 2 (4%) and inferio-temporal BRVO was seen in 2 (4%). Amongst the age related macular degeneration non-exudative ARMD was seen in 6 (12%), exudative ARMD was seen in 4 (8%) and Atrophic ARMD was seen in 3 (6%).

Table 1 : Association Between Different Variables With Their Outcome

Variable	Outcome		P value
	Alive (N=43)	Dead (N=7)	
Age			
≤50 years	7(77.8)	2(22.2)	0.048*
51-60 years	12(100)	0(0)	
61-70 years	14(93.3)	1(6.7)	
71-80 years	7(87.5)	1(12.5)	
>80 years	3(50)	3(50)	
Sex			
Male	24(85.7)	4(14.3)	1.000
Female	19(86.4)	3(13.6)	
Diagnosis			
Ischemic stroke	36(87.8)	5(12.2)	0.595
Hemorrhagic stroke	7(77.8)	2(22.2)	
Hypertensive retinopathy			
Grade 1	5(100)	0(0)	0.086
Grade 2	10(100)	0(0)	
Grade 3	8(88.9)	1(11.1)	
Grade 4	6(60)	4(40)	
No findings	14(87.5)	2(12.5)	
Diabetic retinopathy			
Mild NPDR	4(80)	1(20)	0.007*
Moderate NPDR	9(90)	1(10)	
Severe NPDR	1(25)	3(75)	
PDR	2(100)	0(0)	
No findings	27(93.1)	2(6.9)	
Retinal vascular occlusive changes			
CRVO	2(66.7)	1(33.3)	0.110
ST-BRVO	1(50)	1(50)	
IT-BRVO	1(50)	1(50)	
No findings	39(90.7)	4(9.3)	
ARMD changes			
Atrophic ARMD	2(66.7)	1(33.3)	0.438
Non-exudative ARMD	6(100)	0(0)	

Exudative ARMD	4(100)	0(0)	
No findings	31(83.8)	6(16.2)	
SBP			
>180 mm Hg	7(58.3)	5(41.7)	0.006*
<180 mm Hg	36(94.7)	2(5.3)	
DBP			
>110 mm Hg	7(58.3)	5(41.7)	0.006*
<110 mm Hg	36(94.7)	2(5.3)	
RBS status			
>180	5(62.5)	3(37.5)	0.071
.Within normal limits	38(90.5)	4(9.5)	

*statistically significant

As the age increases incidence of Cerebrovascular accidents increases .Mortality increases as the grading of hypertensive retinopathy increases as evident from our study there was 40% mortality with grade 4 hypertensive retinopathy followed by 11.1% mortality with grade 3 hypertensive retinopathy. With severe NPDR mortality was 75%whereas with mild NPDR there was only 1 death.

Mortality was twice among the patients who had systolic blood pressure more than 180mmHg i.e., 5 death whereas there was only 2 deaths among patients that was having systolic blood pressure less than 180mmHg. Higher the SBP,DBP there will be more of MAP therefore higher the mortality as evident with p value <0.005.

DISCUSSION

It is evident from our study that patients who had systolic blood pressure more than 180mmHg and diastolic more than 110mmHg had mortality of 41.7% which is statistically significant with p value <0.005 which is comparable to Kumaravelu et al¹⁸;therefore recording the initial blood pressure plays a crucial role in the prognosis and outcome. In our study amongst the CVA patients ischemic stroke was 82% whereas hemorrhagic stroke was 18%. Retinal abnormalities including potential blinding was seen in 68% among the Hypertensives, among the Diabetics it was 42%, 14%had RVO and 26% had macular degenerative changes. It is nearly comparable to the Nigerian study¹⁹ (57.4%), Singapore report²⁰ (59%),Riaz Z. et al (60%)²¹.

There are certain limitations to our study like examining patients after pupillary dilation , this may not be feasible in all patients. Secondly underreporting cases of retinal abnormalities due to non-availability of sensitive instruments like digital retinal camera..

CONCLUSION

Clinical professionals may be able to further customize a risk profile for stroke for each patient by assessing retinal symptoms in addition to other established vascular risk factors. This might provide more precise risk assessment and possibly help direct therapeutic approaches. Individuals with diabetes, hypertension, fundus examinations may be able to offer more details on long-term stroke risk stratification. Other people may be at risk for stroke based on the retinal abnormalities discovered in these patients. For a routine fundus examination and documentation, all patients who appear with hypertension, diabetes, or macular degeneration should be referred to an ophthalmologist.

REFERENCES

1. WHO report :Causes of Death worldwide report December 2020.
2. Hägg S, Thorn LM, Putaala J, Liebkind R, Harjutsalo V, Forsblom CM, Gordin D, Tatlisumak T, Groop PH; FinnDiane Study Group. Incidence of stroke according to presence of diabetic nephropathy and severe diabetic retinopathy in patients with type 1 diabetes. *Diabetes Care* 2013;36(12):4140-4146.
3. Chen R, Ovbiagele B, Feng W. Diabetes and stroke: epidemiology, pathophysiology, pharmaceuticals and outcomes. *Am J Med Sci*. 2016; 35:380-386.
4. Tso MO, Jampol LM. Pathophysiology of hypertensive retinopathy. *Ophthalmology*. 1982;89:1132-1145.
5. Patton N, Aslam T, Macgillivray T, Pattie A, Deary IJ, Dhillon B. Retinal vascular

image analysis as a potential screening tool for cerebrovascular disease: A rationale based on homology between cerebral and retinal microvasculatures. *J Anat*. 2005;206:319-348.

6. Goto I, Katsuki S, Ikui H, et al. Pathological studies on the intracerebral and retinal arteries in cerebrovascular and noncerebrovascular diseases. *Stroke*. 1975;6:263-269.
7. Lindley RI, Wang JJ, Wong MC, Mitchell P, Liew G, Hand P, Wardlaw J, De Silva DA, Baker M, Rochtchina E, Chen C, Hankey CJ, Chang HM, Fung VS, Gomes L, Wong TY. Retinal microvascular abnormalities in acute lacunar stroke: a cross-sectional study. *Lancet Neurol*. 2009;8:628-634.
8. Schneider R, Rademacher M, Wolf S. Lacunar infarcts and white matter attenuation Ophthalmologic and microcirculatory aspects of the pathophysiology. *Stroke*. 1993;24:1874-1879.
9. Walsh JB. Hypertensive retinopathy. Description, classification, and prognosis. *Ophthalmology*. 1982;89:1127-1131.
10. ETDRS Research Group. Grading diabetic retinopathy from stereoscopic color fundus photographs -- an extension of the modified Airlie House Classification. ETDRS Report Number 10. *Ophthalmology*. 1991;98:786-806.
11. Wong TY, Klein R, Couper DJ, Cooper LS, Shahar E, Hubbard LD, Wofford MR, Sharrett AR. Retinal microvascular abnormalities and incident stroke: The atherosclerosis risk in communities study. *Lancet*. 2001;358:1134-1140.
12. Dimmitt SB, West JN, Eames SM, Gibson JM, Gosling P, Littler WA. Usefulness of ophthalmoscopy in mild to moderate hypertension. *Lancet*. 1989; 1: 1103-1106.
13. Wise GN, Dollery CT, Henkind P. *The Retinal Circulation*. New York: Harper and Row; 1971.
14. Kempen JH, O'Colmain BJ, Leske MC, Haffner SM, Klein R, Moss SE, Taylor HR, Hamman RF. The prevalence of diabetic retinopathy among adults in the united states. *Arch Ophthalmol*. 2004;122:552-563.
15. Hayreh SS. Prevalent misconceptions about acute retinal vascular occlusive disorders. *Prog Retin Eye Res*. 2005;24:493-519.
16. Wong TY, Larsen EK, Klein R, Mitchell P, Couper DJ, Klein BE, Hubbard LD, Siscovick DS, Sharrett AR. Cardiovascular risk factors for retinal vein occlusion and arteriolar emboli: The atherosclerosis risk in communities & cardiovascular health studies. *Ophthalmology*. 2005;112:540-547.
17. Klein R, Klein BE, Moss SE, Meuer SM. The epidemiology of retinal vein occlusion: The beaver dam eye study. *Trans Am Ophthalmol Soc*. 2000; 98: 133-141; discussion 141-133.
18. Kumaravelu S, Johri S, Mukerji JD, Pradhan AB. Intracerebral haemorrhage. *JAPI* 2001;49:49.
19. Routine retinal examination in patients with acute stroke in Ahmadu Bello University Teaching Hospital , Shika -Zaria, Nigeria Emmanuel R. Abah, Obiako O.R.1, Mahmoud-Ajeigbe A.F., Audu O.2.
20. The sixth report of the Joint National Committee on Prevention, Detection, Evaluation and Treatment of High Blood Pressure. *Arc Intern Med* 1997; 45: 360-72.
21. Riaz Z, Ahmed K, Srivastava S. Fundoscopic profile in patients presenting with acute haemorrhagic stroke in a tertiary care hospital, *Global J for Research analysis*, July 2017, Volume 6 : 107.