



ORIGINAL RESEARCH PAPER

Dentistry

**FUSION AND GEMINATED
MAXILLOMANDIBULAR FOURTH MOLARS:
REPORT OF CASES SERIES**

KEY WORDS:

supernumerary teeth, fourth molar, distomolars, fusion, gemination, oral surgery

Prof. Dr. Mehmet Dalkiz	DDS., PhD., Private Practice, MD Clinic, Boulevard Maurice Herbette 21, 1070, Anderlecht, Brussel, Belgium.
Aysenur Ozer	DDS., MD Clinic, Boulevard Maurice Herbette 21, 1070, Anderlecht, Brussel, Belgium.
Ibrahim Serhat Dalkiz	Dental Student, MD Clinic, Boulevard Maurice Herbette 21, 1070, Anderlecht, Brussel, Belgium.

ABSTRACT

Introduction: The presence of supernumerary teeth is a relatively uncommon dental anomaly. It is even rarer to encounter patients with distomolar teeth, commonly referred to as fourth molars. The occurrence of supernumerary teeth is indeed an unusual dental anomaly, and it is a rarity for patients to have impacted fourth molars in all quadrants. The gemination or fusion of maxillary and mandibular posterior teeth is even more infrequent. There are few reports of gemination and fusion involving third or fourth molars. **Case Series Presentation:** This article describes the clinical, radiological, and surgical approaches used to address the cases of nine patients who presented with maxillary and mandibular fourth molars diagnosed via panoramic x-ray. Routine radiographic examinations revealed impacted lower third molars in addition to the fourth molars. It was decided to extract the impacted teeth causing the patients' complaints. The impacted third and fourth molars were extracted under local anesthesia. One of these extracted teeth exhibited fusion, while the other exhibited gemination. **Aim:** This study aims to describe the fourth molar teeth found in nine patients who visited our clinic due to pain and/or orthodontic discomfort, as well as the fusion and gemination of these teeth, along with the surgical treatments administered. **Conclusion:** Accurate diagnosis can help prevent postsurgical complications and streamline the endodontic, prosthodontic, periodontal, orthodontic, and clinical management of such cases. Tooth extraction surgery was the chosen clinical procedure to address the impacted teeth.

INTRODUCTION

Supernumerary teeth are defined as extra teeth present in the dental arch beyond the normal count (1, 2). These are rare developmental anomalies resulting from processes occurring during odontogenesis. Most supernumerary teeth are believed to develop due to horizontal proliferation or hyperactivity of the permanent or primary tooth lamina (3-5). These teeth can appear as single or multiple, unilateral or bilateral, in either one or both jaws (6-9). They can be located in any area of the dental arch and may fuse with the third molars (10, 11). In terms of shape, they can be conical, composite odontoma, or tuberculate and may resemble normally occurring teeth, in which case they are referred to as supplemental teeth. They can be erupted or unerupted (12-34). Since they are typically asymptomatic, they are often discovered through routine x-ray examinations (15-17). The exact etiology of supernumerary teeth remains unknown, although there are suggestions that they may result from reversion or embryological aberrations leading to hyperactivity of the permanent or primary dental lamina (17, 18). It has also been suggested that they may arise from the division of a developing tooth germ, giving rise to the development of multiple individual teeth (3-6, 9, 11-25, 27, 28, 31, 32-49).

Etiology of Supernumerary Teeth: The etiology of supernumerary teeth has not yet been completely clarified, and various theories have been suggested regarding this anomaly. These theories include hereditary disorders, horizontal proliferation of the dental lamina, and abnormal embryological formation. Environmental factors may also play a role (18, 19, 26, 27).

The most frequently affected areas for supernumerary teeth are the region of the upper incisor (mesiodens) and the region of the third molars (19, 20). Those in the incisor region are referred to as mesiodens, those in the molar region are called paramolars, and those in the fourth molar region are termed distomolars. Supernumerary teeth can be classified chronologically, morphologically, topographically, and orientation-wise. They can be categorized chronologically as

pre-milk, primary, permanent, post-permanent, or complementary. Morphologically, they can be conical, tuberculate, supplemental, or odontoma-shaped. Topographically, they can be mesiodens, paramolar, distomolar, or parapremolar. In terms of orientation, they can be vertical, reverse, or transverse (27, 36, 37). Paramolars are rudimentary and are located in the lingual or vestibular region relative to molar alignment. Distomolars, also known as distomolar or retromolar, are situated distally or posteriorly to the third molars. Fourth molars or distomolars typically have a rudimentary shape and are usually retained or included teeth (19, 21-23, 27).

Fourth molars, or distomolars, are situated distally to the third molars and typically have a rudimentary shape. They are usually impacted and rarely erupt into the oral cavity, making their discovery through radiographs common (24). The morphology and size of fourth molars may resemble that of a normal tooth. They can be found unilaterally or bilaterally in both jawbones. While supernumerary teeth are not uncommon, fourth molars are extremely rare (34). Mandibular distomolar teeth are exceptionally rare. The incidence of fourth molars is between 0.02% and 0.16%, with a very rare occurrence of 1.15% in the upper jaw and 0.021% in the lower jaw. Their prevalence in the general population is very low, ranging from 0.1% to 3.8% (2-5). Supernumerary teeth are most commonly found in the maxilla (19, 20, 49), with a higher frequency in men than in women (21). Distomolar teeth may remain asymptomatic or may be discovered incidentally during routine radiological examinations. Early diagnosis, proper evaluation, and appropriate treatment of supernumerary teeth are essential (3, 24, 25, 27, 29, 39-41, 50).

Variations in Distomolars; Distomolars can exhibit heteromorphic characteristics, with atypical morphology, including a cone-shaped crown with a rudimentary root or a tuberculated crown with tubercles and a single, curved root. They can also be eumorphic and resemble normal teeth, sometimes exhibiting infundibular (funnel-shaped) characteristics with crown invaginations or molariform shapes resembling premolars or molars. Distomolars can

have a normal morphology with a fully developed crown, a single root, and clear differentiation from adjacent third molars, or they can deviate from the normal morphology. These distomolars may either fully erupt and align themselves in the dental arch or remain partially or completely impacted. In most cases, undiscovered distomolars do not cause complications within the dental arch or oral cavity (3,21,22,25,30).

Treatment of Supernumerary Teeth: These teeth rarely erupt into the oral cavity and are typically discovered through dental radiography. Early diagnosis, accurate clinical assessment, and appropriate clinical treatment are crucial for providing care to patients with supernumerary teeth (32). There are two main ways to treat supernumerary teeth: extraction (21) and, in specific cases, the maintenance of the tooth in the dental arch with frequent clinical follow-up. Supernumerary molars should be extracted when they do not erupt, when they are misaligned with permanent teeth, or when they cause cystic injuries, sub-acute pericoronitis, gingival inflammation, periodontal abscesses, ameloblastoma, fistulae, or root resorptions. The decision to treat supernumerary teeth depends on their position and the likelihood of them causing pathological changes or disrupting the dental arch (21,23,25).

Extraction of Supernumerary Teeth: Extractions must be performed with great care, and it is imperative that they are carried out by a dental surgeon with expertise in this field to minimize the risk of damaging the dental follicle or reducing the enamel epithelium of the roots of adjacent permanent teeth. Special attention should also be paid to preventing ankylosis or eruption of these teeth. The dental practitioner must be vigilant for potential complications such as damage to the lower alveolar artery and nerve, jaw fracture, as well as perforation of the pterygomaxillary space, maxillary sinus, or orbit (21,24,25).

Case Series Report: In this case series, we aimed to present a case series of maxillary and mandibular fourth molars, which are rarely reported in the literature.

Case Series

Case One: A 17-year-old male patient visited our dental clinic with complaints of orthodontic issues and a desire for orthodontic treatment. Afterward, the patient was seated in the dentist's chair, and a clinical examination was conducted. The clinical evaluation revealed no dental caries, periodontal problems, or signs of pathological conditions within the oral cavity. The intraoral examination showed that all teeth were present, except for the third molars. The patient had orthodontic problems. It was determined that the patient was generally in good health. During the physical examination, the maxillofacial appearance was found to be normal, and no anomalies other than orthodontic dental issues were detected in the intra-oral examination. Additionally, there was no history of any other medical conditions, and the patient did not provide any relevant medical history. He appeared to be healthy, without any features suggestive of a syndrome (Figure 1, 2, and 3).

A routine panoramic radiographic examination revealed impacted upper and lower third molars, as well as unerupted bilateral right upper and unilateral right lower fourth molars (Figure 4). All three fourth molars were rudimentary in shape and smaller than the existing molars.

In this case, due to the patient's orthodontic complaint, it was decided to extract the impacted third and fourth molars under local anesthesia. The surgery was performed under local anesthesia. After the areas were anesthetized by blocking the inferior nerves, a mucoperiosteal flap was prepared, and a sulcular incision was made starting from the mesiobuccal edge of the second molar to its distal surface. A relaxing

incision was made in the mesial region without cutting the interdental papilla. After lifting the flap, an osteotomy was performed using a low-speed handpiece and a round (tungsten carbide) bur with sterile saline irrigation. The third molar was removed first, allowing better access to the fourth molar. After the tooth extraction, the bone cavity was curetted, and the socket was rinsed with saline. The flap was repositioned and secured with 3.0 silk sutures. Subsequently, the superior alveolar nerve on the right side was blocked, and the upper third molar was extracted. The same procedures were applied for the surgical removal of the unerupted third molars in the opposite left lower and upper regions. After curettage of the bone cavity, rinsing with physiological saline, and achieving hemostasis, 3.0 silk sutures were applied. The sutures were removed ten days later. Postoperative follow-up at one, three, and six months showed a satisfactory recovery without any complications (Figure 5, 6, and 7). Orthodontic treatment was initiated and is ongoing with the use of a fixed appliance.

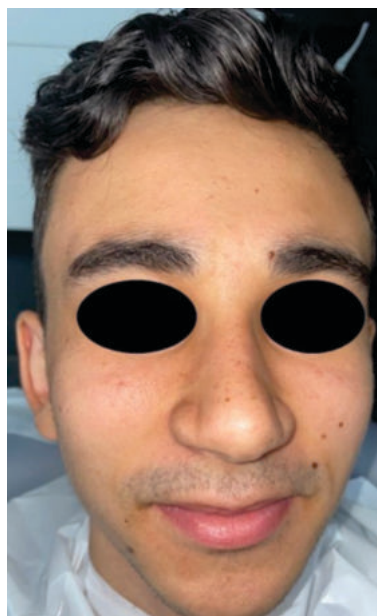

Figure 1: Facial View Of The Patient

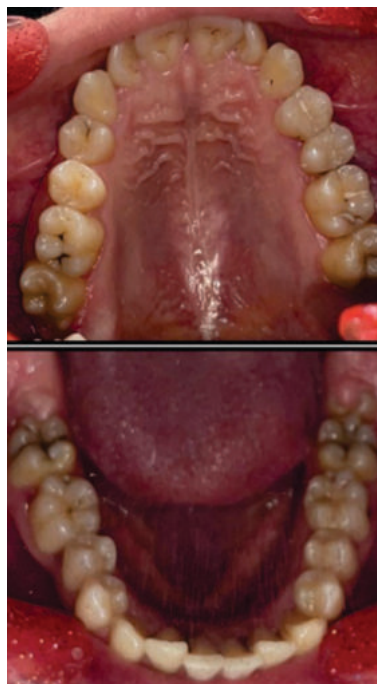

Figure 2: Clinical Photograph Of The First Patient

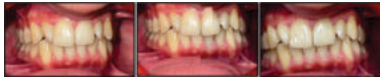

Figure 3: Intra Oral View Of First Patient

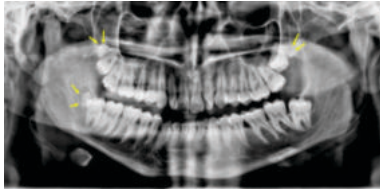

Figure 4: This panoramic dental X-ray reveals the presence of both upper and lower third molars, as well as bilateral upper and right lower fourth molars situated behind the third molars, as indicated by the arrows. It serves as a "pre-orthodontic treatment orthopantomogram," displaying impacted mandibular and maxillary third molars, as well as right mandibular and maxillary distomolars, totaling four impacted third molars and three fourth molars.

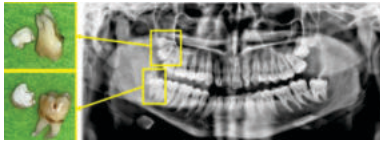


Figure 5: This radiographic view displays the region just before the extraction of teeth 18, 28, and 48, along with the presence of supernumerary upper left-right and lower fourth molars. Additionally, it provides a clinical view of the area following the extraction of teeth 18 and 48, as well as the supernumerary lower and upper-right fourth molars.

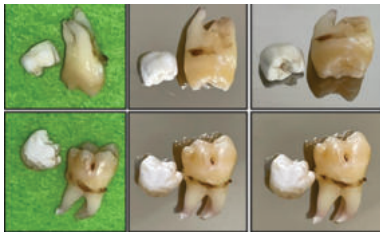


Figure 6: Picture Of The Impacted Third Molars And Distomolars Post-operatively

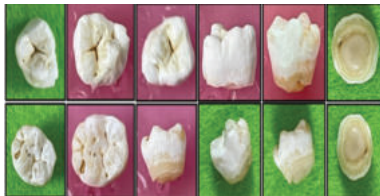

Figure 7: View Of Extracted Distomolars From Different Surfaces

Case Two: A 21-year-old female patient sought treatment at our dental clinic for the extraction of her impacted teeth. Dental X-rays indicated impacted third molar teeth on the right side of the lower and upper jaw, along with an additional tooth (the fourth molar) on the right side of the upper jaw. The clinical assessment revealed a patient in overall good health, with no signs of dental caries or injuries in the oral cavity (both inside and outside). Furthermore, there was no family history of supernumerary teeth (ST) or other dental anomalies among her relatives.

Radiographic evaluation (Fig. 8) showed unerupted third molars in the mandibular and maxillary right regions (18, 48) and an upper right third molar (maxillary right) that appeared to be overlaid on the fourth molar. The dental X-ray clearly displayed the fourth molar impacted behind the lower and upper right third molars (18; 48) (Fig. 8). The utilization of X-rays played a crucial role in the planning of oral surgical procedures (Figs. 9-13).

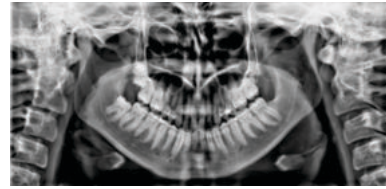


Figure 8: This panoramic dental X-ray displays the lower and upper left third molars, with the fourth molar located behind the third molar. The panoramic radiograph further highlights the presence of a fourth molar in the maxillary right region, seemingly overlapping with the third molar, along with an unerupted mandibular right third molar.

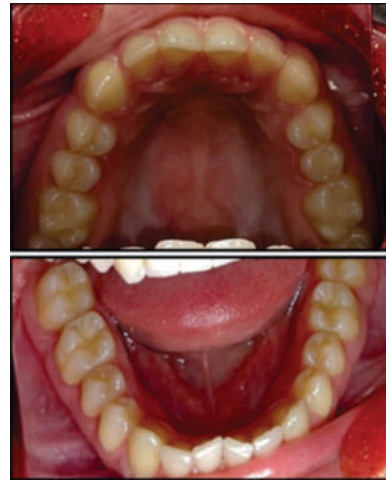


Figure 9: Clinical Photograph Of The Second Patient's Intraoral Occlusal View

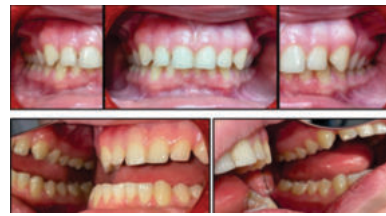

Figure 10: Intra Oral View Of The Second Patient

Following the surgical procedures, with regional anesthesia administered via the upper posterior alveolar nerves, anterior and medial, in addition to the larger palatal nerves, tooth 18, 48, and the upper right fourth molar were extracted. The surgery was carried out in compliance with established clinical protocols for bucco-maxillofacial surgery.

The patient was prescribed the following medications according to the clinical protocol: amoxicillin/clavulanate potassium 875 mg/125 mg, 2 tablets, oral administration, 12 hours x 7 days; diclofenac sodium 50 mg, 2 tablets, oral administration 8/8 hours x 3 days; chlorhexidine gluconate 0.12%, rinse three times daily x 7 days. Post-surgical follow-up examinations were conducted on days 10, 15, and 30 after the surgical intervention. The patient exhibited positive progress without experiencing any complications.

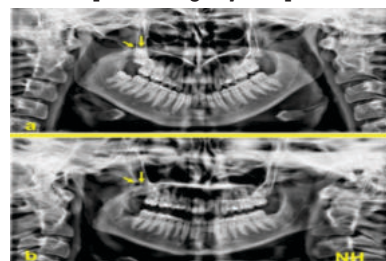


Figure 11: Panoramic Radiographies Of The Patient

Before And After Surgical Intervention.

A: Panoramic Radiography Of The Region Before Dental Surgery.

B: Panoramic Radiography Of The Same Region Taken Seven Days After The Surgery, For The Purpose Of Follow-up.

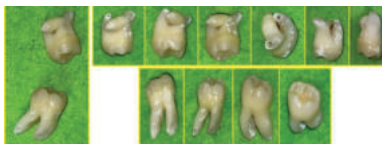

Figure 12: Tooth 18, And 48 And The Fourth Molar After Surgery.

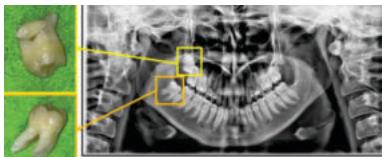


Figure 13: Radiographic View Of The Area Just Before Extraction And Clinical View Of The After Extraction Of Tooth 18 And 48 And The Supernumerary Upper-right Fourth Molar.

Case Three: A 22-year-old male patient in good physical condition presented to our clinic with a complaint of pain in the lower third molar area. There were very few periodontal problems. All teeth, except the third molars, were present in the mouth. The patient reported pain in the third molar region, indicative of an impacted tooth. Panoramic radiography revealed that the left and right maxillary and mandibular third molars (18, 28, 38, 48) were unerupted, and the right mandibular fourth molar was fused to the third molar (twin tooth/geminated molar) (Figure 14).

The panoramic radiographs revealed an unerupted atypical tooth with two crowns, suggesting a radiological diagnosis of a wisdom tooth with fused supernumerary teeth. The geminated molar appeared larger than the existing molars and was attached to the third molar, resembling a twin tooth or a geminated molar. Additionally, this radiograph showed that some teeth had composite and amalgam fillings. It was decided to extract the upper and lower unerupted teeth complaining of pain. The use of X-rays has been extremely useful in planning oral surgeries (Figure 15-18).

Due to the patient's complaint of pain, it was decided to extract the impacted third and fourth molars under local anesthesia. The surgery was performed under local anesthesia. After blocking the lower nerves and anesthetizing the areas, a mucoperiosteal flap was prepared, and a sulcus incision was made, beginning from the mesiobuccally edge of the second molar and ending at its distal surface. A relaxing incision was made in the mesial region without cutting the interdental papilla. After lifting the flap, an osteotomy was performed using a low-speed handpiece and a round (tungsten carbide) bur with sterile saline irrigation. The twin molars were extracted, and after tooth extraction, the bone cavity was curetted. The socket was irrigated with saline, and the flap was repositioned and secured with 3.0 silk sutures. Hemostasis was performed.

The patient was prescribed the following medications according to the clinical protocol: amoxicillin/ clavulanate potassium 875 mg/125 mg, 2 tablets for oral administration every 12 hours for 7 days; diclofenac sodium 50 mg, 2 tablets for oral administration every 8 hours for 3 days; chlorhexidine gluconate 0.12%, to be used as a rinse three times daily for 7 days. The stitches were removed ten days later, and satisfactory recovery was observed without any complications during the first, third, and sixth-month postoperative follow-ups. Subsequently, the same surgical

procedure was applied to the other unerupted third molars for one-month intervals, and the patient continued to show positive development without complications. An examination of the extracted third molar revealed that the tooth was separated by a distinct groove on the buccal and lingual surfaces. The third molar had a single root and appeared to be an incomplete division of the tooth, leading to the diagnosis of gemination. In this case, surgical extraction of the tooth was performed, and the extracted tooth displayed dual dimensions and a deep furrow where the union of both germs had occurred, confirming the diagnosis of a geminated third molar or twin molar.

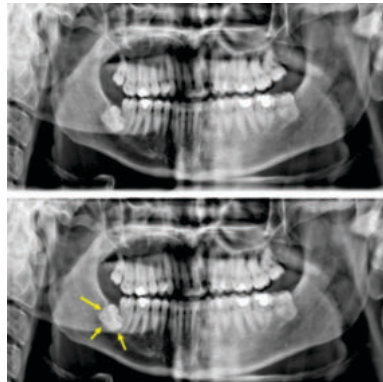


Figure 14: : Panoramic Radiography Taken Before Dental Surgery. The Panoramic Dental X-ray Clearly Shows The Presence Of Fourth Molars Located Behind The Maxillary Right And Left Third Molars.

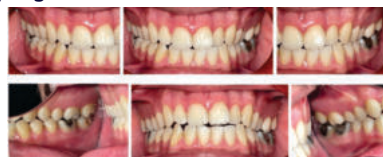

Figure 15: Intra Oral View Of The 22-year-old Male Patient

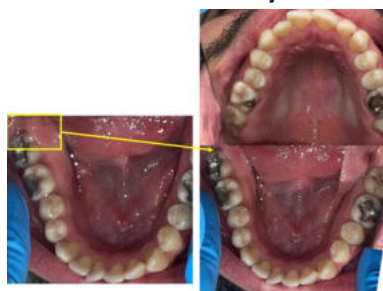


Figure 16: Occlusal View Of The 22-year-old Male Patient

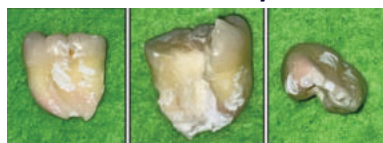

Figure 17: Appearance Of Geminated(twin) Molar (tooth 48 And The Fourth Molar) After Surgery.

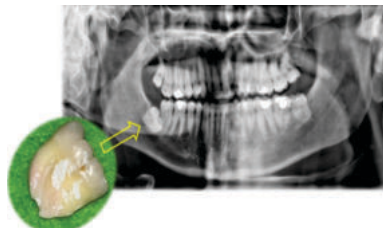


Figure 18: Radiographic View Of The Area Just Before Extraction And Clinical View Of The After Extraction Of Tooth 48 And The Supernumerary Lower-right Fourth Molar (geminated/twin Molar).

Case Four: A 54-year-old male patient visited our clinic seeking relief from pain in his right mandibular second premolar (tooth number 45), which had a metal porcelain crown and was sensitive to percussion. The patient exhibited periodontal issues. Notably, the right maxillary second molar was absent, while a fourth molar was observed distal to the maxillary right third molar. No clinical signs or symptoms suggestive of an impacted tooth were present. Panoramic radiography revealed the absence of the right maxillary second molar (previously extracted) and the presence of the right maxillary fourth molar (Figure 19). This radiograph also indicated that the right mandibular first and second premolars, along with the right maxillary first premolar, had undergone endodontic treatment. Furthermore, some of the teeth displayed composite and amalgam fillings. In response to the patient's complaint of pain, it was decided to remove the metal porcelain crown from the left mandibular second premolar, which was also painful, and perform endodontic retreatment. The procedure was conducted under local anesthesia. The crown was removed, and the canal was meticulously cleaned using endodontic instruments and canal antiseptics, following routine endodontic treatment protocols. Once the tooth became asymptomatic, the crown was re-cemented. Following this, the patient received periodontal treatments, and a follow-up schedule was established with monthly visits initially and later transitioning to quarterly follow-ups.

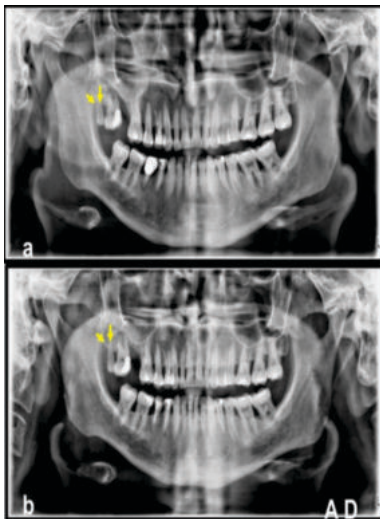


Figure 19: Panoramic dental X-ray displaying the fourth molars located behind the maxillary right third molars. Additionally, it includes panoramic radiographs taken before endodontic treatment (tooth number 45) and during the endodontic treatment process.

Case Five: A 51-year-old male patient presented to our dental clinic for a routine examination. He had no significant medical history, systemic diseases, allergies, or habits such as smoking or alcohol consumption. Notably, the upper right second molar was missing. The patient had a metal-supported porcelain (metal fused porcelain) bridge between the upper left first premolar, and the upper second molar was restored with a porcelain crown fused to metal. Clinical examination revealed that the patient maintained good oral hygiene, and his intraoral soft tissues were found to be in a healthy condition. Additionally, clinical examination revealed the presence of a fourth molar tooth distal to the patient's left maxillary third molar. The patient had restorations in place using amalgam for some of his teeth. In the panoramic radiograph, unerupted supernumerary fourth molar teeth were observed, located distal to the left maxillary fourth molar and in the region of the previously extracted right maxillary third molar tooth (Figure 20). The patient declined surgical removal of the impacted maxillary right fourth molar tooth.

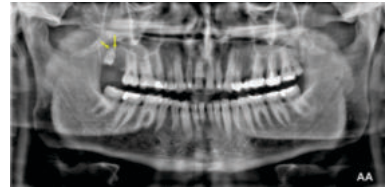


Figure 20: Panoramic Dental X-ray Displaying The Fourth Molars Located Behind The Maxillary Left And Right Third Molars.

Case Six: A 17-year-old male patient presented for a routine dental examination at our clinic. Following the examination, the patient was comfortably seated in the dentist's chair, and a clinical assessment was performed. No clinical evaluation revealed any dental caries, periodontal issues, or signs of pathological formations within the oral cavity. Upon intraoral examination, it was determined that all teeth were present except for the third molars. The patient displayed orthodontic disorders.

The physical examination of the patient, including the maxillofacial region, was within normal parameters. No anomalies other than orthodontic dental disorders were detected during the intraoral examination. Additionally, there was no known history of any other medical conditions or relevant contributory medical history. The patient appeared healthy and did not exhibit any features suggestive of a syndrome. Routine panoramic radiographic examination revealed the presence of impacted superior and inferior third molars, along with unerupted bilateral left and right lower fourth molars (Figure 21). All the fourth molars had a rudimentary shape, resembling dental germs, and were smaller in size than the existing molars. Once again, it should be noted that the patient displayed no features suggestive of any syndrome. Although surgical removal of impacted maxillary and mandibular third molars, as well as mandibular left and right fourth molar teeth, was recommended, the patient declined the procedure.

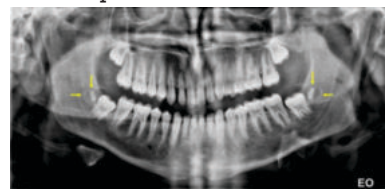


Figure 21: Panoramic dental x-ray showing the maxillary and mandibular impacted third molars and bilateral mandibular fourth molars located behind the maxillary left and right impacted third molars.

Case Seven: A 24-year-old male patient visited our dental clinic due to a crown fracture of the upper left second premolar. Following his arrival, the patient was comfortably seated in the dentist's chair, and a thorough clinical examination was conducted. No clinical evaluation revealed any dental caries, periodontal issues, or signs of pathological formations within the oral cavity. It was observed that all teeth were present except for the third molars. The patient displayed orthodontic disorders. The patient was generally in good health. During the physical examination, the maxillofacial appearance was within normal limits. In the intraoral examination, composite fillings were noted in teeth 11, 12, 16, 24, 26, 36, 46, and 46, in addition to the presence of orthodontic dental disorders. Furthermore, there was no known history of any other medical conditions, and no contributory medical history was reported. The patient presented a healthy appearance with no features suggestive of any syndrome (Figure 22). Routine panoramic radiographic examination revealed impacted superior and inferior third molars. Additionally, it revealed unerupted unilateral left maxillary fourth molars (Figure 17). The fourth molar displayed a rudimentary shape, resembling dental germs,

and was smaller than the existing molars. In the same radiograph, endodontic treatment was evident in teeth 11, 12, and 25, and there was excessive crown destruction on tooth number 25. Following the assessment, it was decided to perform post-core restoration on tooth number 25. The treatment was successfully completed with post-core restoration during the same session. It is important to note that the patient declined surgical removal of impacted maxillary and mandibular third molars, as well as the maxillary left fourth molar tooth.

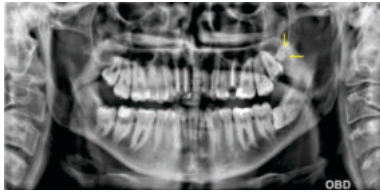


Figure 22: Panoramic dental x-ray showing the maxillary and mandibular impacted third molars and unilateral left maxillary fourth molars located behind the maxillary impacted third molars.

Case Eight: A 25-year-old male patient visited our dental clinic for a routine oral and dental examination. Following his arrival, the patient was comfortably seated in the dentist's chair, and a thorough clinical examination was conducted. No clinical evaluation revealed any dental caries, periodontal problems, or signs of pathological formations within the oral cavity. It was observed that all teeth were present. The patient displayed overall good health. During the physical examination, the jaw- facial appearance was normal, and in the intraoral examination, composite fillings were detected in some of his teeth. Furthermore, there was no known history of any other medical conditions, and no contributory medical history was reported. The patient presented a healthy appearance with no features suggestive of any syndrome (Figure 23). Routine panoramic radiographic examination revealed that the lower right third molar was missing, while the lower left and maxillary third molars were present, and the upper right and left fourth molars were not erupted (Figure 23). The fourth molars displayed a rudimentary shape, resembling dental germs, and were smaller than the existing molars. In the same radiograph, it was evident that composite restorations were made in some teeth. Despite the clinical findings, the patient declined surgical removal of the impacted upper fourth molars.

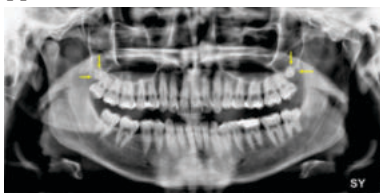


Figure 23: Panoramic dental x-ray showing the maxillary bilateral maxillary fourth molars located behind the maxillary third molars.

Case Nine: A 34-year-old male patient came to our dental clinic for a routine oral and dental examination. Afterward, the patient was seated in the dentist's chair, and a clinical examination was performed. There were no clinical evaluations, dental caries, periodontal problems, and no signs of athological formations in the buccal cavity. Intraoral examination revealed that all teeth were present, indicating the patient's general health. In the physical examination of the patient, the jaw- facial appearance was normal. During the intraoral examination, composite fillings were detected in some of his teeth. Additionally, there was no history of any other diseases, and there was no contributory medical history. The patient appeared healthy with no features suggestive of any syndrome (Figure 24). A routine panoramic radiographic examination revealed that the mandibular and

maxillary third molars were present, while the maxillary fourth molars had not erupted (Figure 24). The fourth molars had a rudimentary shape (dental germs) and were smaller than the existing molars. Furthermore, the routine panoramic radiographic examination indicated that endodontic treatment and composite restorations had been performed on some teeth. The patient refused surgical removal of the impacted upper fourth molars.

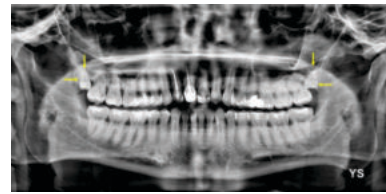


Figure 24: Panoramic dental x-ray showing the maxillary bilateral maxillary fourth molars located behind the maxillary third molars.

DISCUSSION

As described by Schofield et al. (22), fourth molars, which very rarely erupt in the oral cavity, are generally only discovered through radiography, as happened in this clinical case. This paper describes the diagnosis and treatment of a supernumerary right mandibular and maxillary fourth molar. Late eruption or unsuccessful eruption of permanent teeth in supernumerary teeth can lead to several issues, including the displacement of adjacent teeth, malocclusions, misalignment of permanent teeth, pericoronitis, periodontal inflammation, periodontal abscesses, cysts, tumors, and root reabsorption. In such cases, early extraction is recommended (15, 25, 29, 35, 36). Early diagnosis, proper evaluation, and appropriate treatment of supernumerary teeth are essential (31). This case report details the diagnosis and treatment of a very rare case involving the presence of two fourth molars.

Among supernumerary teeth, distomolar teeth are relatively rare. The rarity of distomolar teeth in the population makes it difficult to determine their incidence (5, 34, 35, 37-43). Çentürk MF, Yıldırım D (43), Gündüz K, Çelenk P. (44), Shahzad KM, Roth LE. (45), Kaya E et al. (46), Kurt H et al. (47), Mitsea et al. (48), and Arslan et al. (21) have reported that the frequency of distomolars varies between 0.11% and 0.95% depending on the jaws. Fourth molar teeth are seen more frequently in the upper jaw than in the lower jaw (13, 21, 27, 40). However, there is limited literature on the occurrence of distomolar teeth on the right or left side in the upper or lower jaw. Mitsea et al. (48) reported that distomolars are more common on the right side than on the left side. Kaya et al. (46) noted that of the 27 distomolar teeth they observed in the upper jaw, 14 were on the right, 13 on the left, and 1 of the 3 distomolar teeth they observed in the lower jaw were on the left, with 2 on the right. Çentürk MF, Yıldırım D (43), found that 1 of the 5 dystomolar teeth observed in the lower jaw was on the right and 4 on the left, while 16 dystomolar teeth observed in the upper jaw were evenly distributed on both sides. In our case, the 17-year-old male patient had fourth molars in both the right mandible and right maxilla.

Supernumerary teeth can appear unilaterally or bilaterally, with bilateral supernumerary teeth being less common (48, 49). Concerning unilateral or bilateral distomolar teeth, Kurt et al. (47) reported that 9 out of 45 patients (20%) had bilateral distomolar teeth. Gündüz and Çelenk (44) reported this rate as 33%, Kaya et al. (46) as 30%, and Shahzad and Roth (45) as 45%. In Çentürk MF, Yıldırım D's (43) study, 16.67% of the distomolars observed were bilateral. In this case, the fourth molar (distomolar) teeth were unilateral.

When the teeth are smaller than their normal size, it is referred to as microdont. Distomolars are typically rudimentary, conical, and microdont. Kökten (52) and Shahzad and Roth (45) stated that distomolars are generally smaller than third

molars. Gündüz and Çelenk (44) reported that 75% of the distomolars were microdont, while 25% had a normal appearance in their study of 40 cases on distomolar teeth. Supernumerary teeth with a normal morphology are referred to as "supplementary teeth," but they are usually more often rudimentary in shape and smaller in size (6, 37, 38, 54). Stafne (63) reported that most upper distomolars are blunt, multi-pointed, and much smaller than third molars (26). In the current case, the fourth molars were found to be rudimentary in shape and smaller in size than the third molar.

Such supernumerary teeth may or may not erupt into the oral cavity; if they do erupt, they may lead to malalignment of the dentition due to crowding (47, 48). Most distomolar teeth are impacted, and their diagnosis can only be made radiologically. Gündüz and Çelenk (44) reported that approximately 90% of distomolars are impacted, while Shahzad and Roth (45) reported this rate as 100%. Kaya et al. (46) reported that most of the distomolars were buried in their study, whereas Arslan et al. (21) reported that 21 out of 29 distomolars were unerupted. In Türk MF, Yıldırım D's (43) study, they found that out of the 24 distomolar teeth observed, 9 (23.81%) had erupted, while 32 (76.19%) were found to be impacted. In some cases, such teeth may be discovered during routine radiographic evaluations (37-43). In this study, a patient presented with orthodontic complaints, and fourth molars were detected during radiographic evaluation. The unerupted third and fourth teeth were believed to be causing orthodontic issues.

Supernumerary teeth are generally observed more frequently in men than in women, with male-to-female ratios ranging from 2:1 to 5:1 (44, 45, 49-57). Studies examining the gender distribution of distomolar teeth have shown varying results. Shahzad and Roth (45) and Kaya et al. (46) reported a 1:1 ratio, while Grimanis et al. (16) found no significant difference between men and women regarding the incidence of distomolar. In contrast, Arslan et al. (21) reported a ratio of 16:7, and Kurt et al. (47) reported a ratio of approximately 2:1. Gündüz and Çelenk (44) determined the male-to-female ratio as 2:3 in favor of women. Grimanis et al. (16) reported no gender difference in the prevalence of supernumerary molars, while some other studies found that males were more often affected (14, 21). Taking gender into consideration, these teeth are more frequently found in males than females, with an average ratio of 2:1 (21, 39, 57). The higher prevalence of supernumerary teeth in males has been observed in studies from other parts of the world as well. A Jordanian study among 152 teenagers showed a significantly higher incidence of supernumerary teeth in male subjects with a male-to-female ratio of 2.2:1 (57). The prevalence of fourth molars studied in a Japanese population is 2%, and it appears to be more common in black patients, with a higher incidence in the maxilla unilaterally (46, 55, 57-60). In this study, we present a male patient with unilateral distomolar teeth.

Supernumerary teeth can pose problems for the eruption and alignment of normal teeth. If embedded or erupted supernumerary teeth persist, they may lead to the narrowing of the normal dentition, delays in eruption, malposition, dental caries or gingival problems, as well as root resorption and cyst formation when impacted (4). In some cases, supernumerary teeth may be asymptomatic, as in the present case. In our case, the supernumerary teeth were asymptomatic. Considering all these factors in their treatment, it is recommended to extract supernumerary teeth that cause complications and to periodically follow up asymptomatic teeth that do not cause complications (46, 60). Panoramic radiographs play a crucial role in the diagnosis of distomolars, and the physician should remain vigilant about the presence of distomolar in cases of infection and pain in the molar region (49). Cone Beam Computed Tomography (CBCT) or CT can be included in the detailed examination (5, 21, 48). In this study, distomolar teeth were diagnosed through

panoramic radiography examination.

The surgical extraction of distomolars is indicated when there are inflammatory complications, chronic pain, or orthodontic reasons. When planning for distomolar extraction, a list of factors should be taken into consideration. These factors include the location and accessibility of the teeth during surgery, potential problems with their removal, and the possibility of complications that may occur during or after the surgery (54). The treatment can take two forms: removal of the supernumerary tooth, or in selected cases, maintaining the tooth in the arch with frequent observation. The decision on whether supernumerary teeth require treatment is based on their position and the likelihood of causing any pathological changes or disruption to the dental arch (60). In our case, surgery was performed to remove the distomolar teeth to ensure the success of orthodontic treatment.

In this case, we opted for the extraction of the tooth (5, 20, 42, 61, 62) and supernumerary teeth (fourth molars). To avoid additional trauma or injury to adjacent teeth, we chose to address this case by performing only one surgical procedure, as described by other authors (40, 53, 59-65). No postoperative complications were observed. However, if the teeth had remained in the oral cavity, the patient would have needed to visit the doctor periodically for clinical management and take radiographs to prevent and/or minimize the risk of future problems. Gemination or fusion is a rare occurrence in the maxillary and mandibular posterior teeth. There are only a few reports of geminated and fused third molars and fourth molars in the literature (66-68).

Variations in the number, size, and form of teeth are not uncommon findings. Fusion is the union of two teeth, which can be present with only one pulp chamber and a confluence of enamel and dentin, as in gemination. Alternatively, there may be two separate pulp chambers with union only of the dentin or cement (69, 70). These anomalies involving the permanent dentition are very rare (0-0.8%), with the majority of cases seen in anterior teeth (69, 71). The congenital absence of the adjacent tooth from the dental arch can differentiate fusion from gemination (69, 70). Such anomalous teeth can lead to a series of complications like malocclusion, caries, tooth misalignment, arch asymmetry, and functional problems (69, 72). Among the nine fourth molar cases presented in this study, one had gemination and one had fusion.

None of our cases had a history of orofacial trauma. Differentiating between gemination and fusion can be challenging and is usually confirmed by counting the number of teeth in the area and radiological evaluation (73). A radiographic consideration is the difference in root configuration often seen between fusion and gemination. In the case of fusion, there are usually two separate root canals, whereas in gemination, there is usually one large common root canal (74). Considering all these factors, it is a rare event. On the other hand, it could be fusion? Fusion can be variable depending on the stage of germ development; the pulp chamber and the canals might be linked or separate (75). In the case of fusion between the third molar germ and the fourth molar, this fusion would occur in the initial stage of third molar maturation and stage 4 of the third molar germ. This germ follows the growth and development of the third molar germ. However, it would be possible considering the initial stage of development of other fourth molar germs? Diagnostic difficulties arise when fusion occurs between a "normal" tooth and a supernumerary tooth, resulting in a full complement of teeth and giving the clinical appearance of gemination (74). Therefore, there may be fusion or gemination of the third molar with a supernumerary tooth (the fourth molar).

Tooth gemination and fusion are anomalies that occur in odontogenesis. The exact etiology of geminated teeth is

unclear, but various local and systemic factors are thought to be responsible for developmental disorders. There are reports suggesting that physical stress resulting from infectious inflammatory processes, endocrine effects, ionizing radiation, or local traumatic interventions during tooth development can lead to close contact between tooth buds, resulting in fusion (76-79). Fused teeth are usually asymptomatic. Due to the difficulty in determining whether a tooth is fused or geminated, it has been suggested that these anomalies be referred to by a neutral term such as "double tooth." The term "twin" or "double tooth" has sometimes been used to denote the production of identical structures through division, resulting in one normal and one supernumerary tooth. Various clinical and radiographic criteria are used to distinguish fusion from gemination. When clinically fused teeth are counted as one tooth, a complete complement of teeth usually means that this phenomenon represents gemination; less than a complete tooth complement usually indicates fusion. Radiographic evaluation is based on the difference in root configuration often seen between fusion and gemination. While in the case of fusion, there are usually two separate canals, whereas in gemination, there is usually one large common root canal. Confusion has still arisen as to whether the abnormal tooth is gemination or fusion.

The extraction of an undiagnosed fused or geminated posterior tooth in the dental arch can lead to further complications. This is because there is a higher likelihood of fracturing the maxillary tuberosity or mandibular bone due to excessive force application when attempting to remove the large tooth (80, 81). Fortunately, no complications occurred in any of our patients who underwent surgical intervention.

The primary goals in treating fusion and gemination cases should be to reduce the risk of caries, periodontal issues, improve aesthetics, and maintain function. Treatment options will be case-dependent and can vary greatly due to the numerous ways in which the tooth may present. A multidisciplinary approach with input from orthodontists, prosthodontists, endodontists, and oral surgeons may be required (80, 82, 83). The treatment decision should take factors such as the location of the tooth, the patient's age, the degree of involvement, and the stage of root development into consideration. In our cases where patients complained of pain and orthodontic irregularity, surgically removing fused, geminated, or separate unerupted fourth molars was deemed necessary.

CONCLUSION

Although supernumerary teeth are considered unusual anomalies, they are not as rare as previously reported. Their presence, alongside other dental anomalies and potential complications, holds clinical significance. The occurrence of multiple distomolars is especially rare in children.

Identifying this anomaly may serve as an indicator of potential complications, pathologies, other dental anomalies, syndromes, and familial associations.

Gemination and fusion of teeth, although rare, are clinically important due to their potential side effects and implications for other teeth. Appropriate and careful diagnosis is essential to prevent postsurgical complications in such cases.

The development of a fourth molar in both the maxillary and mandibular arch is a rare phenomenon that typically cannot be detected through routine dental examination, particularly when located distal to the third molar. Radiographic imaging is necessary for its identification. If any symptoms arise, these supernumerary teeth should be removed.

In conclusion, distomolars can vary in shape and size, appearing normal or abnormal, and may or may not be associated with potential complications. Distomolars in the

mandibular arch are less commonly observed and often remain unnoticed during routine dental examinations when situated distally to the third molar. These distomolars are typically discovered as incidental findings on routine radiographic examinations.

REFERENCES

1. Leco Berrocal MI, Martin Morales JF, Martinez Gonzalez JM. An observational study of the frequency of supernumerary teeth in a population of 2000 patients. *Med Oral Pathol Oral Cir Bucal* 2007;12:134-138.
2. Ghaemina H , Meijer GJ, Soehardi A, Borstlap WA, Mulder J, Bergé SJ.: Position of the impacted third molar in relation to the mandibular canal. Diagnostic accuracy of cone beam computed tomography compared with panoramic radiography. *Int J Oral Maxillofac Surg* 2009;38:964-971.
3. Mosquirira VMV, Melendez MTE, Flores FH. Presence of the fourth molar. Literature review. *Revista Odontológica Mexicana*. 2018;22 (2):103-17.
4. Sumida T, Murase R, Yoshimura T, Aramoto T, Ishikawa A, Hamakawa H. A Case of Impacted Supernumerary Fourth Molar in the Bilateral Mandibular Ramus. *Oral Science Int.*, 2009;106-108. [https://doi.org/10.1016/S1348-8643\(09\)80006-2](https://doi.org/10.1016/S1348-8643(09)80006-2)
5. Kokten G, Balcioğlu H, Buyukertan M. Supernumerary Fourth and Fifth Molars: A Report of Two Cases. *J Contemp Dent Pract*. 2003; 4(4):67-76. <https://doi.org/10.5005/jcdp-4-4-67> PMID:14625596;
6. Karikal A, Karikal A. Fourth molar tooth in the mandible: A rare case report. *SRM J Res Dent Sci*. 2014; 5:280-282. <https://doi.org/10.4103/0976-433X.145165>
7. Ramsaran AS, Barclay S, Scipio E, Ogunsalu C. Non-syndromal multiple buried supernumerary teeth: report of two cases from the Englishspeaking Caribbean and a review of the literature. *West Indian Med J.*, 2005; 54: 334-336.
8. Wang XX, Zhang J, Wei FC. Autosomal dominant inheritance of multiple supernumerary teeth. *Int J Oral Maxillofac Surg* 2007;36:756-758.
9. Hou G, Tsai C. Fusion of maxillary third and supernumerary fourth molars: case report. *Aust Dent J* 1989;34:219-222.
10. Gunduz K, Muğlalı M. Non-syndromic multiple supernumerary teeth: a case report. *Contemp Dent Pr* 2007; 8:81-88.
11. Christopher S., Savitha A., Lazarus F, et al. Fourth Molars - Bilateral Impaction-A Case Report. *J Dent Res Updat* 2014; 1:79-81.;
12. Garvey M., Barry H., Blake M. Supernumerary teeth- an overview of classification, diagnosis and management. *J Can Dent Assoc* 1999; 65: 612-616.
13. Jaiyeoba OO, IfesanyaJU. Mandibular and maxillary distomolars in the orthodontic child patient: a report of 3 cases. *Ann Ibd. Pg. Med* 2018;16(2): 177-180
14. Liu J. Characteristics of premaxillary supernumerary teeth: a survey of 112 cases. *ASDC J Dent Child* 1995;62:262-265;
15. Gallas M., Garcia A. Retention of permanent incisors by mesiodens. *Br Dent J* 2000; 188:63-64..
16. Grimanis C., Kyriakides A., Spyropoulos N. A survey on supernumerary molars. *Quintessence Int.*, 1991;22:989-995.;
17. Hattab F, Yassin O., Rawashdeh M. Supernumerary teeth: report of three cases and review of literature. *J Dent Child.*, 1994;61:382-393.
18. AnisuzzamanMD, Alam MK, Afrin Khan SRA. Four Impacted Fourth Molars in Adult Patient. *International Medical Journal* 26(6):525-526, 2019
19. Piattelli A, Tetè S..Bilateral maxillary and mandibular fourth molars. Report of a case. *Acta Stomatol Belg*. 1992;89:57-60.;
20. Kokten G. Supernumerary fourth and fifth molars: A report of two cases. *The journal of contemporary ental practice*. 2003;4(4):67-76.
21. Arslan A, et al. The frequency of distomolar teeth in a population of urban Turkish adults: a retrospective study. *Oral Radiology*. 2009;25(2):118-22.;
22. Schofield J J. Multiple symmetrical supernumerary molar teeth. *Br Dent J* 1973; 135:455-56.
23. Koo S, Salvador PS, Ciuffi Júnior J, de Silva Júnior AR.; Bilateral maxillary fourth molars and a supernumerary tooth in maxillary canine region a case report. *SADJ* 2002 57:372-74.).
24. Raley L L.: Four impacted fourth molars. *Oral Surg oral med oral pathol* 1975; 40:564-65.
25. Nazif MM, Ruffalo RC, Zullo T: Impacted supernumerary teeth: a survey of 50 cases. *JADA* 1983; 106:201-204.
26. Mosquirira VMV, Melendez MTE.: Flores FH. Presence of the fourth molar. Literature review. *Revista Odontológica Mexicana*. 2018;22 (2):103-17.
27. Khandelwal P, Hajira N. Supernumerary teeth - Fourth Molars: Bilateral maxillary distomolars. An extremely rare case report. *Journal of Applied Dental and Medical Science*. 2016;2(1).
28. Qaradaghi IF. Supernumerary tooth: Report of a case of a fourth mandibular molar. *Rev Clin Pesq Odontol*. 2009;5(2):157-60.
29. Mittelman HR, et al. Fourth molars in the maxilla and mandible. *Oral Surgery Oral Med Oral Pathol*. 1963;16:1297-1300.
30. Moore J R. Surgery of the mouth and jaws. Blackwell scientific publications, Oxford, 1985; 373-375.
31. Ali FM, Aridhi WH, Hommedi AM, Altharawi RA, Khan MA. A Rare Case Series: Impacted Distomolars. *Open Access Maced J Med Sci.*, 2019;1-4, <https://doi.org/10.3889/oamjms.2019.637>
32. Khandelwal P, Hajira N. Supernumerary teeth - Fourth Molars: Bilateral maxillary distomolars An extremely rare case report. *Journal of Applied Dental and Medical*
33. Ata-Ali F, Ata-Ali J, Peñarrocha-Oltra D, Peñarrocha-Diago M. Prevalence, etiology, diagnosis, treatment and complications of supernumerary teeth. *J Clin Exp Dent* 2014;6:e414-418.
34. Cassetta M, Altieri F, Giansanti M, Di-Giorgio R, Calasso S. Morphologi- , Calasso S. Morphological and topographical characteristics of posterior supernumerary molar teeth: An epidemiological study on 25,186 subjects. *Med Oral Patol Oral Cir Bucal* 2014;19:e545-549.
35. Kara M., Aktan AM, Ay S. Characteristics of 351 supernumerary molar teeth in Turkish population. *Med Oral Patol Oral Cir Bucal* 2012; 17:e395-400.
36. Marzola, C. et al. Fundamentos de cirurgia buco maxilo facial. Bauru: Ed. Independente, 2005.;

37. Marzola C. et al. Presença de um quarto molar no seio maxilar? ev. Deontology Moderno., 1980. Science. 2016; 7(9):9-1.
38. Anthonappa R P, King N M, Rabie A B. Prevalence of supernumerary teeth based on panoramic radiographs revisited. *Pediatr Dent.*, 2013; 35:257-261
39. Nayak G, Shetty S, Singh I, Pitalia D. Paramolar A supernumerary molar: A case report and an overview. *Dent Res J (Isfahan)* 2012; 9:797-803.
40. Stafne E C. Supernumerary teeth. *Dent Cosmos* 1935; 74: 653-659.
41. Luten J R. The prevalence of supernumerary teeth in primary and mixed dentitions. *J Dent Child* 1967; 34: 346-353.
42. Regezi J A, Sciubba J J, Jordan C K, editors. *Textbook of Oral Pathology: Clinical pathological correlations*. 4th ed. Philadelphia: W.B.Saunders Co.; 2003. p. 374
43. Öentürk MF, Yıldırım D. Retrospective Analysis Of Distomolar Frequency EÜ Dişhek Fak Derg 2017; 38_3: 158-163
44. Gündüz K, Çelenk P. Distomolarlar üzerine retrospektif bir çalışma. *Türkiye Klinikleri J Dental Sci* 2006; 12:83-86.
45. Shahzad KM, Roth LE. Prevalence and management of fourth molars: a retrospective study and literature review. *J Oral Maxillofac Surg* 2012; 70: 272-275.
46. Kaya E, Güngör K, Demirel O, Özütlük Ö. Prevalence and characteristics of non-syndromic distomolars: a retrospective study. *J Investig Clin Dent* 2015; 6:282-286.
47. Kurt H, Suer BT, Senel B, Avşere H. A retrospective observational study of the frequency of distomolar teeth in a population of 14.250 patients. *Cumhuriyet Dent J* 2015; 18:335-342.
48. Mitsea A, Vardas E, Papachatzopoulou A, Kalfountzos G, Leventis M, Tsikalakis K. The frequency of non-syndromic distomolar teeth in a Greek population sample? *J Clin Exp Dent*. 2015; 7:e589-594.
49. Timocin N, Yalacin S, Ozgen M, et al. Supernumerary molars and paramolars. *J Nihon Univ Sch Dent* 1994; 36: 145-150
50. Neville B, Damm D, Allen C. Bouquet J: *Oral Maxillofacial Pathology*. 2. ed, Saunders, Philadelphia, 2002, s.71.
51. Pindborg JJ. *Pathology of the dental hard tissues*. Copenhagen: 1970.
52. Kökten G, Balciolu H, Büyüktan M. Supernumerary fourth and fifth molars: a report of two cases. *J Contemp Dent Pract* 2003; 15:67-76.
53. Faqeeh MA, Al Absi FS, Alrefai MA, Ali FM. A case report of bilateral impacted mandibular fourth molars. *International Journal of Contemporary Medical Research*. 2017; 4(11):2306-7
54. Anisuzzaman MMD, Alam MK, Afrin A, Khan SR. Four Impacted Fourth Molars in Adult Patient. *International Medical Journal* 2019; 26(6): 525-526,
55. Yusuf WZ. Non-syndromic multiple supernumerary teeth: Literature review. *J Can Dent Assoc* 1990; 56: 147-149.
56. El Nassry. Characteristics of hyperdontia in premaxillary region: A survey of 300 cases. *Dent Res* 1996; 75: 1279.
57. Rajab L D, Hamdan M A. Supernumerary teeth: Review of the literature and a survey of 152 cases. *Int J Paediatr Dent* 2002; 12:244-254
58. Peker I, Kaya E, Darendeliler-Yaman S. Clinical and radiographical evaluation of non-syndromic hypodontia and hyperdontia in permanent dentition. *Med Oral Patol Oral Cir Bucal* 2009; 14:393-397.
59. Clementini M, Ottria L, Pandolfi C, Agrestini C, Barlattani A. Four impacted fourth molars in a young patient: a case report. *Oral and Implantology*. 2012; 5(4):100-3.
60. Koo S, et al. Bilateral maxillary fourth molars and a supernumerary tooth in maxillary canine region a case report. *SADJ*. 2002; 57:372-74.
61. Shultsman M, Taicher S. Fourth molars in the maxilla and mandible—a rare phenomenon. *Refuat ha-pehveha-shinayim*. 2003; 20(2):35.
62. Pereira VX, da Silva AP, Carlesso JS, Campos MF. A Rare Case of a Maxillary Fourth Molar: Case Report. *J Hum Growth Dev*. 2019; 29(1): 125-128. <http://dx.doi.org/10.7322/jhgd.157763>
63. Camilleri GE. Concomitant hypodontia and hyperdontia. *Br Dent J*. 1967; 123:338-349.
64. Moore JR. *Surgery of the mouth and jaws*. Blackwell scientific publications; Oxford: 1985. pp. 373-75. 19.
65. Szkaradkiewicz AK, et al. Supernumerary teeth in clinical practice. *J Biol Earth Sci*. 2011; 1:M1-M5.
66. Zhu M, Liu C, Ren S, Lin Z, Miao L, Sun W. Fusion of a supernumerary tooth to right mandibular second molar: a case report and literature review. *Int J Clin Exp Med* 2015; 8(8): 11890-11895
67. Sandeep S, Kumar GJ, Potdar S, Bhanot R, Amit S, Vathare AS, Tiwari RVC, Harshitha B. Rare case of gemination of mandibular third molar—a case report. *J Family Med Prim Care* 2020; 9(05):2577-2579.
68. Brauer HU, Bartols A. Gemination of an Erupted Mandibular Third Molar: A Short Presentation of an Exceptionally Rare Clinical Occurrence. *European Journal of Dentistry* 2023; 09(20):1-5
69. Camargo AJ, Arita ES, Watanabe PC. Fusion or gemination? An unusual mandibular second molar. *Int J Surg Case Rep*. 2016; 21: 73-77. doi: 10.1016/j.ijscr.2015.12.010
70. Tannenbaum K.A., Ailing E.E., Anomalous tooth development: case reports of gemination and twinning, *Oral Surg. Oral Med. Oral Pathol*. 16 (1963)883-887.
71. Stabholz A, Friedman F. Endodontic therapy of an unusual maxillary permanent first molar. *J Endod* 1983; 9(7) 293-295.
72. Dhindsa A, Garg S, Damle SG, Opal S, Singh T. Fused primary first mandibular macromolar with a unique relation to its permanent successors: a rare tooth anomaly. *Eur J Dent*. 2013; 7: 239-242.
73. Altug-Atac A.T., Erdem D. Prevalence and distribution of dental anomalies in orthodontic patients. *Am J Orthod Dentofacial Orthop*. 2007; 131:510-514.
74. Kelly J.R. Gemination fusion, or both? *Oral Surg. Oral Med. Oral Pathol*. 1978; 45(4): 655-656.
75. Ballal S., Sachdeva G.S., Kandaswamy D., Endodontic management of a fused mandibular second molar and paramolar with the aid of spiral computed tomography: a case report. *J Endod*. 2007; 33: 1247-1251.
76. Sandeep S.; Kumar, G.J.; Potdar, S.; Bhanot, R.; Vathare, A.S.; Tiwari, R.V.; Harshitha, B. Rare case of gemination of mandibular third molar—A case report. *J Family Med Prim Care* 2020, 9:2577-2579.
77. Shrestha, A.M., Marla, V., Shrestha, S., Mahrjan, I.: Developmental anomalies affecting the morphology of teeth—A review. *RSBO* 2015, 12: 68-78.
78. Grover, P.S.; Lorton, L. Gemination and twinning in the permanent dentition. *J Oral Med. Oral Path*. 1985, 59, 313-318.
79. Demircioglu Guler D., Sen Tunc E., Arici N.: Ozkan, N. Multidisciplinary management of a fused tooth: A case report. *Case Rep. Dent*. 2013; 634052.
80. Mahendra, L.; Govindarajan, S.; Jayanandan, M.; Shamsudeen, S.M.; Kumar, N.; Madasamy, R. Complete bilateral gemination of maxillary incisors with separate root canals. *Case Rep. Dent*. 2014; 425343.
81. Hegde, R.; Awan, K.H. Effects of periodontal disease on systemic health. *Dis. Mon*. 2019, 65: 185-192.
82. Grammatopoulos, E. Gemination or fusion? *Br. Dent. J*. 2007, 203, 119-120.
83. Pandya-Sharp, A.; Purry, J. A. Geminated Mandibular Second Molar—A Case Report. *MDPI Reports* 2021, 4, 31. <https://doi.org/10.3390/reports4040031>