



## LIPOMA OF THE INFERIOR ALVEOLAR NERVE CANAL : EXCEPTIONAL LOCATION OF INTRAOSSEOUS LIPOMA

### Surgery

**Hicham Sabani\*** Assistant Professor, Department Of Plastic And Maxillofacial Surgery, Mohammed V Military Hospital, Hassan Ii University, Casablanca, Morocco. \*Corresponding Author

**Karim El Khatib** Professor, Department Of Plastic And Maxillofacial Surgery, Mohammed V Military Hospital, Mohammed V University, Rabat, Morocco

### ABSTRACT

Lipomas are the most commonly occurring soft tissue tumors, being intraosseous involvement very rare, and the jaw is its most uncommon bone location. Thus intraosseous mandibular lipomas constitute a real diagnostic challenge due to the unspecific clinical and radiographic features, therefore, only 28 cases have been reported in the literature. Herein we report an extremely rare case of an intraosseous mandibular lipoma that initially developed in Inferior alveolar nerve canal, characterize with dental cone beam computed tomography, and confirmed with histopathologic analysis after surgery. To the best of our knowledge, our case is one of the first cases of intraosseous mandibular lipomas involving the inferior alveolar nerve canal never been previously reported. Their rarity reinforces the need to document each and every case.

### KEYWORDS

Intraosseous Lipoma, Bone Tumor, Mandible, Inferior Alveolar Nerve Canal.

### INTRODUCTION :

Lipomas are common benign mesenchymal tumors composed of mature adipocytes without cell atypia (1). It is the most frequent benign soft tissue tumor. They may be found wherever fat tissue is present, but lipoma may be also found at intramuscular, retroperitoneal and intraosseous levels (2).

Based on the literature, the overall incidence of intraosseous lipoma represents less than 0.1% of all bone tumors [3,4], and only 29 cases, including this one, have been reported in the mandible since 1948 (5). Until today the etiology and characteristics of these tumors are not clear, stating the importance of documentation of each new case of intraosseous mandibular lipoma (IML).

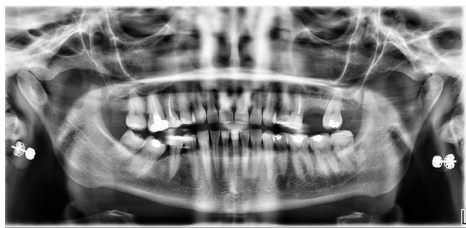Herein we report an extremely rare case of an IML which initially developed in Inferior alveolar nerve canal, characterize with dental cone beam computed tomography (CBCT), and confirmed with histopathologic analysis after surgery.

### CASE REPORT :

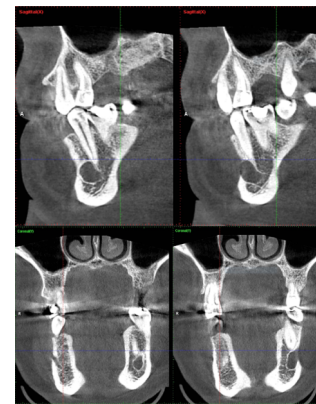An 46-year-old woman patient was referred to our department of Oral and Maxillofacial Surgery by her dentist for a painless unilocular radiolucency located on the left mandibular body, next to the apex of the second pre-molar tooth observed in a Orthopantogram. The patient's general health was good, she had no recalled prior trauma and her past medical history was unremarkable.

The extraoral physical examination revealed no alterations and there is no paresthesia of the lip, the intraoral evaluation revealed no signs of mucosal abnormality or cortical expansion and Cold pulp testing revealed that all left mandibular teeth were vital. There was no accompanying cervical lymphadenopathy.

Orthopantogram (Fig.1) revealed a well-defined, unilocular radiolucency with sclerotic margins in the left mandibular body. The lesion was located adjacent to the foramen of the inferior alveolar nerve canal and entirely within bone. This radiographic appearance was suggestive of a contact between the lesion and the inferior alveolar nerve.



**Fig.1:** Orthopantogram revealing a well-defined, unilocular radiolucency in the left mandibular body, located adjacent to the foramen of the inferior alveolar nerve canal.

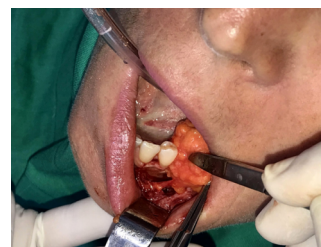

**Fig. 2 :** CBCT showing a solitary well-circumscribed lesion, with sclerotic borders, inside the inferior alveolar nerve canal. Note the canal and foramen enlargement.

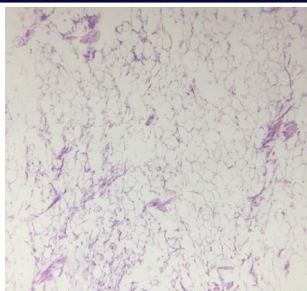
CBCT (Fig.2). showed the presence of a solitary well-circumscribed lesion, round in shape, measuring approximately 10 mm in diameter, with sclerotic borders. Cross-sectional view illustrated a lesion inside the inferior alveolar nerve canal that cause canal and foramen enlargement, and penetrate adjacent soft tissue.

A surgical procedure was undertaken aiming to remove the lesion completely. A buccal mucoperiosteal flap was performed under local anesthesia, exposing the cortical plate. The lesion which was involving the inferior alveolar nerve canal, was excised conservatively (Fig.3). The patient showed no mental nerve paresthesia, and her postoperative recovery was uneventful. The histological examination (Fig.4) using hematoxylin and eosin, revealed a lesion predominantly composed of Mature adipocytes without cytological atypia. Based on these findings, a diagnosis of intraosseous lipoma was made.

No sign of recurrence was observed after six months of follow-up.



**Fig. 3 :** Intraoral view after surgical resection showing an intraosseous lipoma of mandible surrounding the inferior alveolar nerve.



**Fig. 4 : Mature adipocytes show limited variation in size with bland nuclei and no cytological atypia (H&E, magnification x100).**

## DISCUSSION

Lipomas are mesenchymal neoplasms originating from fat cells (6). They are the most commonly occurring soft tissue tumors. Usually occur in subcutaneous tissue, but may occur anywhere that fat cells exist. May occur within muscles, in the mediastinum, along the gastrointestinal tract, in the retroperitoneum, in the brain, along the spinal cord, along nerve and tendon sheaths, within joints, and occasionally within bone.

The most frequent localisations of intraosseous lipoma were the calcaneus (24%) and the femur (22%), the mandible being considered an exceptional location (7).

In fact, The first case of IML was reported by Oringer in 1948 as a radiolucent lesion under a second molar(8), and according to the bibliography only 28 cases of IML have been described. Our case is one of the first cases of IML initially developed in Inferior alveolar nerve canal, never been previously reported.

In 2001, Burik classified according to its 3 possible origins : medullary cavity fat (intramedullary lipoma), periosteum (periosteal lipoma) and, less likely, the adjacent soft tissue that could invade the bone secondarily and appears as a periosteal lipoma (9).

IML tends to affect those between the fourth and the sixth decade of life. It is more common in males than females with a ratio of 1.6 : 1 (9,10).

Most of the intraosseous lipoma are incidental findings on radiographs taken for other purposes. Symptoms, when present, are localized mild pain, swelling or rarely fracture of the affected bone (11).

The most frequent symptoms of the intraosseous lipoma in the jaws are paresthesia and external root resorption.

Radiologically, IMLs typically present as radiolucent lesions with a well-defined sclerotic border (12). The radiolucency results from resorption of pre-existing bone by fat cells. Unilocular radiolucent lesions are considered benign, however, when composed of irregular borders and soft tissue involvement, malignancy should be suspected (13). CBCT and MRI allow more accurate lesion analysis and make it possible to detect specific adipose tissue (12).

Despite the usefulness of all these techniques, histopathology remains the gold standard for diagnosis of lipomas (14). Microscopically, sheets of mature adipocytes without atypia and absence of hematopoietic elements are the essential features (15)

Based on the level of involution, three stages of intraosseous lipomas have been described by Milgram: Stage 1 ; when there is no secondary necrosis, Stage 2 ; when there is partial necrosis, Stage 3 ; when there is complete secondary necrosis and dystrophic calcification, in this case lesions have a higher predisposition towards malignancy (16). Previously reported IMLs are more consistent with stage 1 lesions, including our presented case.

The precise etiology of IML is still controversial. According to many authors, intraosseous lipoma are benign tumors originates from medullary adipose tissue. Others consider this lesion a reactive alteration caused by infarction, infection, or trauma (17). Another hypothesis is that they are simple conglomerations of fatty marrow,

formed as part of the normal ageing bone process (18).

The differential diagnosis of IML includes simple cyst, post-traumatic cyst, aneurysmal bone cyst, giant cell granuloma, ameloblastoma, osteoblastoma, arteriovenous malformations, hemangiomas, infarcted bone, chondrosarcoma, and liposarcoma (19).

Treatment consists of tumor enucleation and curettage when necessary. The prognosis is very good. No recurrence or any malignant changes of IML have been reported [1,20].

## CONCLUSION :

IML are uncommon and are difficult to diagnose. Clinically, the lesion is often silent and radiologically it appears as a radiolucent area. Therefore a histopathological examination is the gold standard for the differential diagnosis. Complete surgical removal is the treatment choice for IML, with no previously reported recurrence. Due to the limited number of cases reported, especially IML involving the inferior alveolar nerve canal, the understanding of the aetiology and features of IMLs continues to evolve, thus reinforcing the importance of documenting each new case.

## REFERENCES

- González-Pérez LM, Pérez-Ceballos JL, Carranza-Carranza A. Mandibular intraosseous lipoma : clinical features of a condylar location. *Int J Oral Maxillofac Surg* 2010 ; 39: 617–20.
- Basheer S, Abraham J, Shameena PM, Balan A. Intraosseous lipoma of mandible presenting as a swelling. *J Oral Maxillofac Pathol*. 2013 ; 17:126-8.
- Manganaro AM, Hammond HL, Williams TP. Manganaro upload to Mendeley. *J Oral Maxillofac Surg* 1994 ; 52:767–9.
- Sanjuan A, Dean A, Garcia B, Alamillos F, Roldan E, Blanco A. Condylar intramedullary intraosseous lipoma: contribution of a new case and review of the literature. *J Clin Exp Dent*. 2017 ; 9:498–502.
- Mehta j and Mishra M. Intraosseous lipoma of the mandible: a case report and short review of the literature. *Oral Surg*. 2018 ; 11(4) : 323-8
- Mc Tighe S, Chernev I. Intramuscular lipoma: a review of the literature. *Orthop Rev* 2014 ; 6(4) : 5618.
- Kapakuya A, Subasi M, Dabak N, Ozkul E. Osseous lipoma: eleven new cases and review of the literature. *Acta Orthop Belg*. 2006 ; 72:603-14.
- Oringer MJ. Lipoma of the mandible. *Oral Surg Oral Med Oral Pa-thol*. 1948 ; 1:1134
- Buric N, Krasic D, Katic V. Intraosseous Mandibular Lipoma : a case report and review of the literature. *J Oral Maxillofac. Surg*. 2001 ; 59:1367-71.
- Hart JA. Intraosseous lipoma. *J Bone Joint Surg Br*. 1973 ; 55:624- 32
- Williams CE, Close PJ, Meaney J, Ritchie D, Cogley D, Carty AT. Intraosseous lipomas. *Clin Radiol* 1993 ; 47:348-50.
- Wa\_sowska J, W\_ojcik S, Koszowski R, Drozdowska B. Intraosseous lipoma of the mandibula: a case report and review of the literature. *Open Med*. 2017 ; 12:45–9.
- Gonz\_alez\_P\_erez LM, P\_erez-Ceballos JL, Carranza-Carranza A. Mandibular intraosseous lipoma: clinical features of a condylar location. *Int J Oral Maxillofac Surg* 2010 ; 39:617–20.
- Epivatianos A, Markopoulos AK, Papanayotou P. Benign tumors of adipose tissue of the oral cavity : a clinicopathologic study of 13 cases. *J Oral Maxillofac Surg*. 2000 ; 58: 1113-1117.
- Campbell RS, Grainger AJ, Mangham DC, Beggs I, Teh J, Davies AM. Intraosseous lipoma : Report of 35 new cases and a review of the literature. *Skeletal Radiol* 2003 ; 32:209-22.
- Milgram JW. Intraosseous lipomas: Radiologic and pathologic manifestations. *Radiology* 1988 ; 167:155-60.
- Sakashita H, Miyata M, Okabe K. Intraosseous lipoma of the maxilla. A case report. *Int J Oral Maxillofac Surg* 1998 ; 27:63–4.
- Basheer S, Abraham J, Shameena P M, Balan A. Intraosseous lipoma of mandible presenting as a swelling. *J Oral Maxillofac Pathol* 2013 ; 17: 126-8
- Sanjuan A, Dean A, Garcia B, Alamillos F, Roldan E, Blanco A. Condylar intramedullary intraosseous lipoma: Contribution of a new case and review of the literature. *J Clin Exp Dent*. 2017 ; 9:e498-e502.
- Cakarar S, Selvi F, Isler SC, Soluk M, Olgac V, Keskin C. Intraosseous lipoma of the mandible: A case report and review of the literature. *Int J Oral and Maxillofac Surg* 2009 ; 38(8): 900-2.