



## ANATOMICAL STUDY OF VARIATIONS IN FORAMEN TRANSVERSARIUM OF CERVICAL VERTEBRAE AND CLINICAL SIGNIFICANCE

### Anatomy

**Suresh Kumar T** Senior Assistant professor, Dept of Anatomy, Govt Vellore Medical College, Vellore, Tamil Nadu

**Satish Kumar S** Senior Assistant professor, Dept of Anatomy, Govt Mohan Kumaramangalam Medical College, Salem-30, Tamil Nadu. Corresponding Author

### ABSTRACT

**Background:** The typical feature of cervical vertebrae is presence of foramen transversarium which exhibit variations in the number, size, shape which may lead to various symptoms. The aim of the present study was to find the variations in the foramen transversarium such as incidence of accessory foramen transversarium, different shape of foramen transversarium and its clinical significance.

**Material and Methods:** This study included 91 dried cervical vertebrae obtained from the Department of Anatomy, Govt Thiruvannamalai Medical college, Thiruvannamalai. All the cervical vertebrae were observed macroscopically for the presence of accessory foramina transversaria on both side. Also the shape and the direction of the main diameter of foramen transversarium were studied and classified into five types.

**Results:** Among the 91 cervical vertebrae, accessory foramen transversarium observed only in 6 cervical vertebrae (6.6%). Out of this unilateral accessory foramen transversarium found in 5 vertebrae (5.5%) and bilateral accessory foramen transversarium found only in one vertebrae (1.1%). Five different shapes of foramen transversarium were noted and Type 1 (round) shape was the prominent (52.2%)

**Conclusion:** The incidence of accessory foramen transversarium in the present study was 6.6%. Accessory foramen transversarium were smaller as compared to the normal foramen and more common in lower cervical vertebrae (C6, C7). Anatomical knowledge of these variations in foramen transversarium will be useful for radiologists in interpretation of x rays, CT, MRI scans of cervical region and also for neurosurgeons, vascular surgeons operating in this region.

### KEYWORDS

Cervical vertebrae, Foramen Transversarium, Accessory Foramen Transversarium, Incomplete Accessory Foramen Transversarium, Vertebral artery

### INTRODUCTION

Foramen transversarium is the cardinal feature of cervical vertebra which transmits the vertebral artery, vertebral vein and sympathetic fibres from the inferior cervical ganglion. The cervical transverse process is a compound structure with foramen transversarium and has ventral and dorsal bars which ends laterally as the corresponding tubercles. These tubercles unite lateral to the foramen by a bar of bone called as costal (intertubercular lamella) [1].

The foramen transversarium shows variations in the size, shape and may be multiple or absent [2]. An accessory foramen transversarium is the smaller posterior part of foramen transversarium which is divided by a fibrous bony bridge, the larger anterior part encloses the artery and the smaller posterior part encloses the vertebral nerve and vertebral vein [4].

The variations in number and size of foramen transversarium results in headache, migraine, fainting attack due to compression of vertebral artery. The etiology for variation may be due to embryological or related to the course of the vertebral artery [3].

The objective of the present study was to analysis of foramen transversarium macroscopically, to study the incidence of accessory foramen transversarium and types of foramen transversarium according to their shape and main diameter.

### MATERIALS AND METHODS

91 cervical vertebrae obtained from the department of Anatomy, Govt Thiruvannamalai Medical college, Thiruvannamalai of unknown sex were studied. The foramen transversarium of cervical vertebrae were studied macroscopically for 1) the presence or absence of foramina, 2) number of vertebrae with unilateral or bilateral accessory foramen transversarium 3) presence of incomplete foramina and their side 4) according Taitz et al [5] the shape and direction of the main diameter, the foramen transversarium were classified into five types (fig 1) (The cervical vertebrae were studied as seen from above in an A-P direction with the body of the vertebrae facing the examiner). Type 1: Round, Type 2: Elliptical with main diameter (Length) antero posterior, Type 3: Elliptical with main diameter transverse (breadth), Type 4: Elliptical with main diameter oblique from right to left, Type 5: Elliptical with main diameter oblique from left to right.

The vertebrae with unilateral, bilateral accessory foramen, incomplete

accessory foramen and the various types of foramen transversarium were photographed with the digital camera.

### RESULTS

In the present study all the vertebrae showed foramen transversarium. Out of 91 cervical vertebrae, only 6 vertebrae (6.6%) showed the accessory foramen transversarium. Among them 4 vertebrae had accessory foramen on the right side (fig 3), 1 had on left side accessory foramen transversarium and one had bilateral accessory foramen transversarium (fig 2).

In this study we also observed one cervical vertebrae having incomplete accessory foramen transversarium on right side and complete accessory foramen transversarium on left side. We also identified another cervical vertebrae having both incomplete foramen transversarium (because of gap between the posterior tubercle and anterior root) and complete accessory foramen transversarium on right side.

The various shapes and direction of main diameter of the foramen transversarium observed and their incidence are given in Table 1. Out of 91 cervical vertebrae, Type 1 Round shape (52.5%) was the commonest shape observed in 48 vertebrae.

### DISCUSSION

Foramen Transversarium is a bony frame work for the vertebral artery in its course from its origin to the posterior cranial fossa [6]. It is formed by vestigial costal element fused to the body and the originally true transverse process of the vertebrae. The vertebral vessels and nerve plexus are caught between the bony parts. A costo transverse bar closes laterally the foramen transversarium, which is a plate of bone which connects the costal element to the original transverse process [5]. Taitz et al also stated that the absence of foramen transversarium at the level of C4 and C6 vertebrae and an absent foramen transversarium could be due to absent vertebral artery [5]. In our study, we observed foramen transversarium in all the cervical vertebrae.

Many studies have been done on morphology of foramen transversarium. One of the study conducted by muralimanju et al on 363 cervical vertebrae only six (1.6%) showed accessory foramen transversarium. Among them five (1.4%) showed bilateral and only one (0.3%) had unilateral accessory foramen transversarium [7].

Kaya et al studied on 22 cervical vertebrae of ancient byzantine population, double foramen transversarium was found in five vertebrae(22.7%), unilateral in 3 and bilateral in 2 vertebrae[3]. In another study Of Patil et al on 175 cervical vertebrae, double foramen transversarium was found in 5.7%, unilateral duplication in 3.42% and bilateral in 2.28%[8].

Out of 200 typical cervical vertebrae studied by Sharma et al accessory foramen were found in 16 vertebrae(8%) among vertebrae between C3-C6, incidence being higher in C6 vertebrae in their study[4]. Taitz et al in their study of 480 cervical vertebrae observed double foramen transversarium in 7% cases[5].

In our present study of 91 cervical vertebrae, the accessory foramen transversarium was found in 6 cervical vertebrae(6.6%). In this 5 vertebrae(5.5%) showed unilateral accessory foramen transversarium and one vertebrae(1.1%) showed bilateral accessory foramen. Thus the incidence of unilateral accessory foramen was more common than bilateral and the accessory foramen were observed only in lower cervical vertebrae(C6,C7).

Our results coincides with previous studies on accessory foramen transversarium of cervical vertebrae. Comparison between the present study and various authors shown in Table 2.

In this study we also observed one cervical vertebrae having incomplete accessory foramen transversarium on right side and complete accessory foramen transversarium on left side. We also identified another cervical vertebrae having both incomplete foramen transversarium and complete accessory foramen transversarium on right side.

Incomplete accessory transverse foramina were found mainly the posterior root possibly due to erosion of bones as the age advances though this was difficult to assess because of lack of information about age in most of these studies and it is documented that tortousity of vertebral artery may cause bony erosion or impede the complete formation of the transverse foramen[9].

The embryogenesis of vertebral artery begins at 32 days and is completed by 40 days. It is formed from the fusion of the longitudinal anastomoses that links cervical intersegmental arteries which branch from the primitive dorsal aorta. The intersegmental arteries eventually regress except for the 7th vessel which forms the proximal portion of the subclavian artery, including the origin of vertebral artery. As the connection of 7th intersegmental vessel to primitive dorsal aorta disappears, the vertebral artery is formed[10]. Fenestration of vertebral artery or its duplication can lead to double foramen transversarium as in case of duplicated arteries which have two origins and their fusion points are in the neck but fenestrated vessels have single origin and divide into two parallel trunks within or outside the vertebral canal[11].

As the Vertebral vessels are the important in the formation of the foramen transversarium, variations in the presence and course of the vertebral vessels will result in variation in foramen transversarium. A narrowing of the foramina indicates narrowness of the vessels and so on.

El Shaarawy et al observed that the accessory foramina transversaria were most common at the lower cervical vertebrae (C5,C6 and C7), mostly in C6 [13].

The surgical anatomy and morphology of foramen transversarium, accessory foramen transversarium is useful for the neurosurgeons and radiologist in the interpretation of radiographic films, CT scans and MRI of cervical region.

The variation in the foramen transversarium can lead to distortion and compression of the vertebral artery, which may lead to neurological symptoms like headache, migraine, fainting attacks and hearing disturbances as this artery supplies the inner ear too[13]. Maintaining the vertebral artery is the important concern during cervical spine surgeries since minor lesions will lead to serious hemorrhage or even death[16].

**RESULTS**

The incidence of accessory foramen transversarium in the present

study was 6.6%. The unilateral accessory foramen was more common than the bilateral. All the accessory foramen were observed in the lower cervical vertebrae (C6,C7) Presence of accessory foramen transversarium could mean variations in the number, the course of vertebral artery. This variations can lead to neurological symptoms due to compression of vertebral artery.

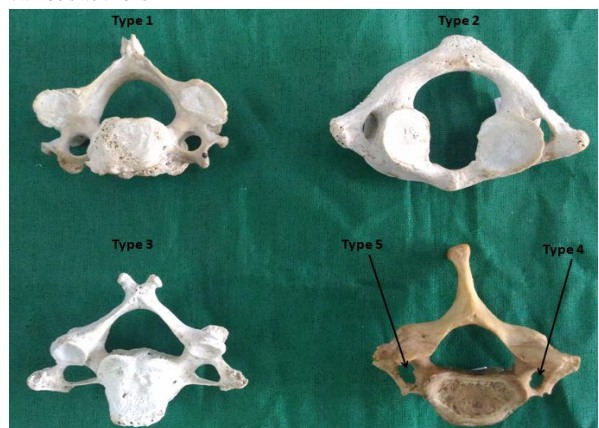Hence the surgical anatomy, morphology of foramen transversarium and its variations is important for radiologist in interpretation of X rays, CT and MRI scans of cervical region and also for neurosurgeons ,vascular surgeons during posterior cervical surgery.

| Shape and Direction of foramen Transversarium                    | Incidence % (Number of Vertebra) |
|--|----------------------------------|
| Type 1: Round  | 52.7(48)                         |
| Type 2: Elliptical with main diameter antero-posterior           | 5.5(5)                           |
| Type 3: Elliptical with main diameter Transverse(breadth)        | 26.4(24)                         |
| Type 4: Elliptical with main diameter oblique from right to left | 7.7(7)                           |
| Type 5: Elliptical with main diameter oblique from right to left | 7.7(7)                           |

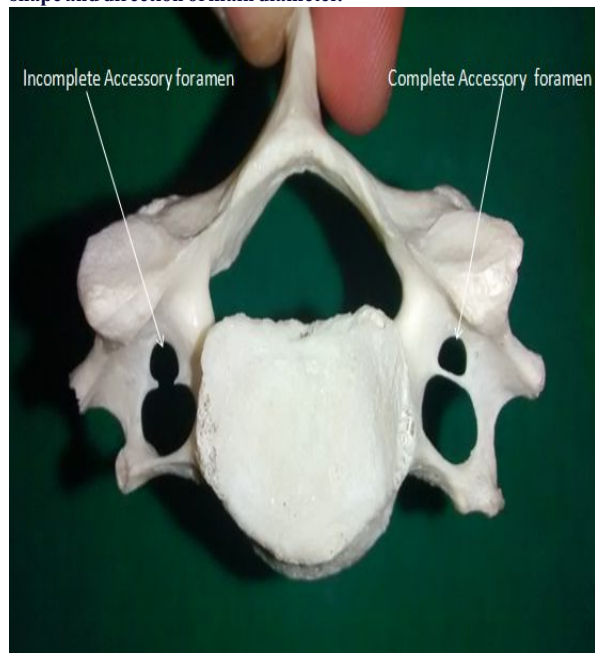
**Table 1: Showing different types of Foramen Transversarium according to Shape and main diameter of foramen transversarium.**

| Author                 | Number of Vertebrae studied | Incidence of Vertebrae with Accessory Foramen Transversarium % | Incidence of Vertebrae with Bilateral Accessory Foramen Transversarium % | Incidence of Vertebrae with unilateral Accessory Foramen Transversarium % |
|------------------------|-----------------------------|--|--|---|
| Taitz et al5           | 480                         | 7  | -  | -   |
| Patil et al8           | 175                         | 5.71   | 2.2  | 3.42  |
| Murali Manju et al7    | 363                         | 1.6  | 1.4  | 0.3   |
| Rathnakar et al12      | 140                         | 5.7  | 1.42   | 3.6   |
| Kaya et al3            | 22                          | 22.7   | 0.76   | 1.14  |
| Ramachandran K et al14 | 120                         | 15.8   | 7.5  | 8.3   |
| Present Study          | 91                          | 6.6  | 1.1  | 5.5   |

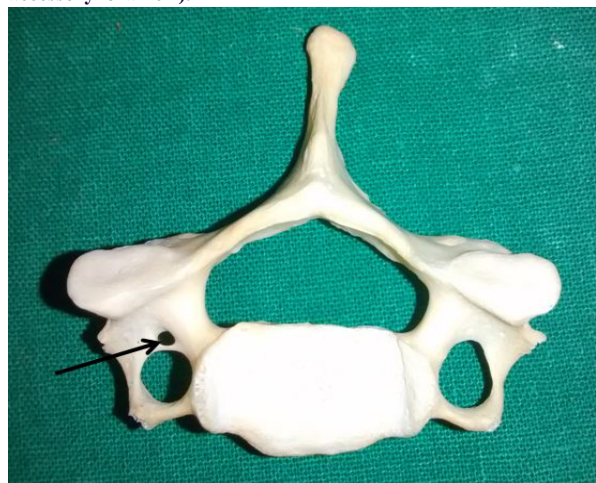**Table 2: Comparison of Studies on Foramen Transversarium by various authors**



**Fig 1 : Five Types Of Foramen Transversarium according to shape and direction of main diameter.**



**Fig 2 : Cervical Vertebra showing Bilateral Accessory foramen (right side incomplete accessory foramen and left side complete accessory foramen).**



**Fig 3 : Cervical Vertebra showing Right side Accessory foramen.**

## REFERENCES

1. Standring S, Ellis H, Healy JC et al. Grays Anatomy. 39th Edition. Elsevier. Churchill Livingstone. 2005;743.
2. Das Srijit, Suri R, Kapur V. Double Foramen Transversaria: An Osteological study with Clinical Implications. *Int Med J* 2005;12:311-313.
3. Kaya S, Yilmaz ND, Pusat S, et al. Double foramen transversarium variation in ancient Byzantine cervical vertebra : preliminary report of an anthropological study. *Turkish Neurosurgery* 2011 ; 21(4):534-538.
4. Sharma A, Singh K, Gupta V, et al. Double foramen transversarium in cervical vertebra. An osteological study. *J.Anat. Soc.India* 2010;59(2):229-231.
5. Taitz C, Nathan H, Arensburg B. Anatomical observations of foramina transversaria. *Journal of Neurology Neurosurgery and Psychiatry* 1978; 41:170-176.
6. Wysocki J, Bubrowski M, Reymond J, Kwiatkowski J. Anatomical variants of cervical vertebra and the first thoracic vertebra in man. *Folia Morphol.*2003;62(4):357-363.
7. Muralimanju BV, Prabhu LV, Shilpa K, et al. Accessory transverse foramina in the cervical spine-Incidence, Embryological basis, Morphology and Surgical importance. *Turkish Neurosurgery*,21(3):384-387.
8. Patil NP, Dhapate SS, Satish P, et al. The study of incidence of accessory foramen transversaria in the cervical vertebra. *Journal of Dental and Medical Sciences* 2014; 13(1): 85-87.
9. S RB, Neginhal DD. Variations in foramen transversarium of atlas vertebra: An osteological study in south Indians. *Int J Res Health Sci.* 2014 Jan31;2(1):224-8.
10. Inoneta C, Omojola MF. MR Angiographic demonstration of bilateral duplication of the extra cranial vertebral artery: unusual course and review of literature. *Am J Neuroradiol.* 2006;27:1304-1306.
11. Mehta G, Shamkumar S, Mokhasi V. Foramina transversaria 'Bipartita'. A study of cervical vertebra. *Int J Cur Res Rev* 2014;6(7):31-34.
12. Rathnakar P, Remya K, Swathi B. Study of accessory foramen transversaria in cervical vertebrae. *NUJHS* 2013; 3(4):97-99.
13. El Shaarawy EAA, Sabry SM, El Gammaroy T, Nasr LE: Morphology and morphometry of the foramina transversaria of cervical vertebrae: A correlation with the position of the vertebral artery. *Aini Medical Journal.* 2010. Accessed December 10, 2010.
14. Ramachandran K, Ravikumar PC, Manavalan MS. A study on the foramen transversarium in cervical vertebrae. *Int J Health Sci Res.* 2014;4(12):178-183.
15. Chaudhari ML, Maheria PB, Bachuwar SP. Double Foramen transversarium in cervical vertebra. Morphology and Clinical importance. *Indian Journal of Basic and Applied Medical research* 2013; 8(2):1084-1088.
16. Riew K: Microscope-assisted anterior cervical decompression and plating techniques for multilevel cervical spondylosis. *Operative Techniques in Orthopaedics* 8:22-33, 1988.