


Biphasic Synovial Sarcoma of the Thyroid Gland – A case report



Medical Science

KEYWORDS : Synovial sarcoma, Biphasic, Thyroid gland

Dr. Pratik Patel	Corresponding author) Fellow in Pathology department, Gujarat Cancer & Research Centre, Ahmedabad, Gujarat, India.
Dr. Birwa Shah	Assistant Professor in Pathology, Gujarat Cancer & Research Centre, Ahmedabad, Gujarat, India
Dr. Ashini Shah	Assistant Professor in Pathology, Gujarat Cancer & Research Centre, Ahmedabad, Gujarat, India.
Dr. Manoj Shah	Professor and Head of Pathology department, Gujarat Cancer & Research Centre, Ahmedabad, Gujarat, India.

ABSTRACT

Aim: Primary biphasic type synovial sarcoma of the thyroid gland is an extremely rare condition. Very few such cases have been reported in the literature. Here we report another case of primary biphasic type synovial sarcoma of the thyroid gland which was diagnosed preoperatively in a 13 years old female patient.

Methods and Results: The tumor showed typical histological and immunohistochemical features of biphasic synovial sarcoma in pre-operative biopsy, fine needle aspiration smears and in excision specimen.

Conclusion: Such case reports may serve as the reference for clinicians and pathologists. Because of the aggressive nature of this tumor, early di-agnosis and comprehensive treatment including wide resection and adjuvant chemo-radiation is required.

Introduction

Synovial sarcoma accounts for about 5% to 10% of all soft tissue sarcomas (1). The mean age at the time of diagnosis is about 30 yr (1). Approximately 85% of this tumor occurs in para-articular regions of the extremities, with a predilection for the lower extremities. Following the extremities, the tumors arise in the head, neck, and trunk (1). Synovial sarcoma has also been described at various anatomic sites including the skin, heart, lung, pleura, prostate, kidney, central nervous system, bone, esophagus, liver, ovary, vulva, peripheral nerve, and mediastinum (1-5). To the best of our knowledge, only five cases of primary synovial sarcoma that originated in the thyroid gland have been reported (6). When synovial sarcomas arise in these unusual sites, recognition and differential diagnosis becomes more difficult. Here, we report a primary synovial sarcoma of the thyroid gland with clinical, histopathological, immunohistochemical features.

Case Report

A 13-years-old female had a chief complaint of a palpable neck mass for 4 years. She had no family or past medical history. The patient first recognized the neck mass 4 years before, and it gradually increased in size with difficulty in swallowing and breathing. All laboratory tests, including thyroid function tests, were unremarkable. The neck computed tomography revealed a large (8.0x6.3x4.3 cm) heterogeneously enhancing lobulated soft tissue density mass arising from mid and lower pole of left lobe of thyroid gland with small specks of calcification within it and causing compression and displacement of trachea and major neck vessels (Fig. 1A). The fine needle aspiration cytology showed cellular spindle cell proliferation with mitosis and bland giant cell like area which correlated with epithelial tubule forming component of tumor on biopsy (Fig. 1B). Biopsy showed classical biphasic pattern of synovial sarcoma (Fig. 1C). Our case is the first case which was diagnosed before surgery.

The patient subsequently underwent total thyroidectomy and cervical lymph node dissection. The mass was well defined with pushing margins measuring 8.0x6.0x4.5 cm in dimensions. The cut surface showed a well-demarcated, lobulated and grayish-white solid mass with firm consistency (Fig. 1D). Microscopically, peripheral normal thyroid tissue with cellular short spindle cells proliferation with mitosis and area of tubule formation

lined by epithelial cells were observed (Fig. 2A&B). Areas of hyalinization and microcalcification were present (Fig. 2C). Focal areas of hemangiopericytoma like pattern were also present. On average, 12 mitotic figures were seen per 10 high-power fields both in epithelial and spindle cells. On immunohistochemical staining, the glandular elements strongly stained with cytokeratin (AE1) (Fig.2E), where as the spindle cells diffusely stained with vimentin (Fig.2D) & BCL2 (Fig. 2F) and focally with epithelial membrane antigen (EMA). Stains for thyroglobulin and thyroid transcription factor-1 (TTF-1) were negative in the tumor cells. On these findings the diagnosis of biphasic type synovial sarcoma, grade-II was given. All resection margins and lymph nodes were free of tumor. The postoperative course of the patient was uneventful. Concurrent chemo-radiation had been planned.

Discussion

Synovial sarcoma arises from pleuripotential mesenchymal cell. It comprises of 5-10% of all soft tissue sarcoma. Most synovial sarcomas arise in the extremities, near the large joints, but do not originate from synovial tissues. Therefore, they can also occur in any other anatomical location, including the head and neck, abdominal wall, and the thoracic cavity (7). Synovial sarcoma arising in the head and neck accounts for 5-10% of all synovial sarcoma. Most of them seem to originate in the paravertebral connective tissue spaces & manifest as solitary retropharyngeal or parapharyngeal masses (1, 8). Synovial sarcoma arising in parenchymal organ is rare. Only 5 cases of synovial sarcoma originating from the thyroid gland have been reported in the literature (6). They are summarized in table 1.

Synovial sarcoma typically affects adolescents and young adults. The age of the previously reported all primary thyroid synovial sarcoma patients were more than 40 except one case (15 year male); suggesting that synovial sarcoma of the thyroid gland tends to develop at an older age, in contrast to synovial sarcoma that originate from soft tissue (9). However in our case it presented in a 13 year old female patient.

According to histologic findings, synovial sarcoma can be classified as biphasic or monophasic. Biphasic synovial sarcoma consists of spindle and epithelial cells which rarely causes diagnostic difficulties. On the other hand, monophasic synovial sarcoma

can exhibit variable patterns and present as diagnostic challenge. Monophasic spindle cell type synovial sarcoma should be distinguished from other spindle cell sarcomas, such as leiomyosarcoma, fibrosarcoma, and malignant peripheral nerve sheath tumor (MPNST) (10, 11). Differential diagnoses should also include carcinosarcoma or spindle epithelial tumor with thymus-like differentiation (SETTLE) (8). Our case showed typical biphasic histologic pattern.

Immunohistochemistry study shows positivity to epithelial markers (EMA, cytokeratins) and Vimentin in most cases of synovial sarcoma. Bcl-2 is widely expressed in the spindle cells, which helps differentiation from other spindle cell tumors (12). CD99 can be positive but CD34 is almost always negative (1). Although characteristic immunohistochemical study with histomorphology confirms the diagnosis of synovial sarcoma in most cases, molecular study for SYT/SSX fusion transcript is the most accurate diagnostic method.

The primary treatment of synovial sarcoma is wide surgical excision to obtain tumor-free margins, because most soft tissue malignancies tend to extend along the fascia. However, this cannot always be accomplished in the head and neck region because of the proximity of the tumor to vital structures. Therefore, a combination of surgery and postoperative radiotherapy is generally recommended. Chemotherapy based on ifosfamide may also be considered as adjuvant treatment or for the treatment of recurrent tumor (8). As described in previous and the current reports, synovial sarcoma arising from the thyroid gland tends to be infiltrative and aggressive, necessitating early and comprehensive treatment (9). In our case, resection was adequate with free margins.

CONCLUSION

Primary biphasic type synovial sarcoma arising from the thyroid gland is extremely rare, and information about prognosis and standard treatment is lacking. We were able to diagnose the case on biopsy and fine needle aspiration cytology. We think that such case reports may serve as the reference for clinicians and pathologists. Because of the aggressive nature of this tumor, early diagnosis and comprehensive treatment including wide resection and adjuvant chemo-radiation is required.

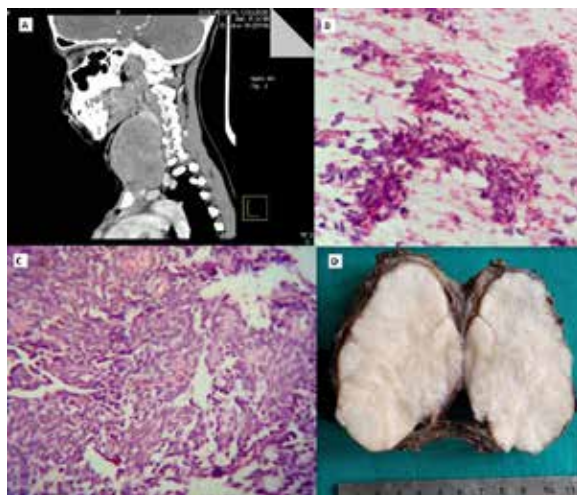


Figure-1. (A) Radiological (CT scan) findings (B) Fine needle aspiration cytology features (H&E stain, 40X) (C) Biopsy showing classical biphasic pattern of synovial sarcoma (H&E stain, 40X) (D) Cut surface of tumor in resection specimen

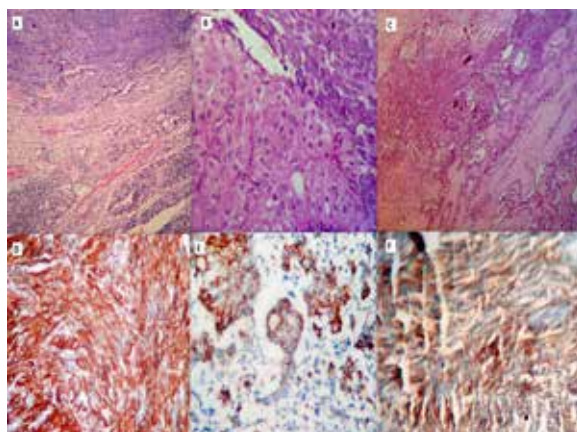


Figure-2. (A, B, & C) Microscopic features of biphasic synovial sarcoma in resection specimen. (D, E & F) Immunohistochemical findings showing vimentin, AE1 and BCL2 positivity

Table 1 Five cases of thyroid synovial sarcoma reported in the literature

Ref.	Sex/age, years	Preoperative diagnosis	Initial treatment	Mono- or biphasic	Adjuvant treatment	Relapse (months after surgery)	Last follow-up (months after surgery)
(6)	M/55	no	surgery	mono-phasic	no	local (0.5 months) CT, surgery, RT	alive without disease (10 months)
(9)	M/60	no	surgery	biphasic	no	local and lung (18 months)	dead of disease (36 months)
[13]	F/72	no	surgery	mono-phasic	no	local and lung (0.5 months)	dead of unknown cause (3 months)
[14]	M/15	no	surgery	biphasic	NA	NA	NA
[15]	F/44	no	surgery	mono-phasic	NA	NA	NA

M = Male; F = female; FNAC = fine-needle aspiration cytology; NA = not available; CT = chemotherapy; RT = radiotherapy.

REFERENCE

1. Weiss SW, Goldblum JR, Enzinger FM. *Enzinger and Weiss's Soft Tissue Tumors*. St. Louis, USA: Mosby 2001; 1483-509. | 2. Nielsen GP, Shaw PA, Rosenberg AE, Dickersin GR, Young RH, Scully RE. Synovial sarcoma of the vulva: a report of two cases. *Mod Pathol* 1996; 9: 970-4. | 3. Smith CJ, Ferrier AJ, Russell P, Danieletto S. Primary synovial sarcoma of the ovary: first reported case. *Pathology* 2005; 37: 385-7. | 4. Holla P, Hafez GR, Slukvin I, Kalayoglu M. Synovial sarcoma, a primary liver tumor--a case report. *Pathol Res Pract* 2006; 202: 385-7. | 5. Suster S, Moran CA. Primary synovial sarcomas of the mediastinum: a clinicopathologic, immunohistochemical, and ultrastructural study of 15 cases. *Am J Surg Pathol* 2005; 29: 569-78 | 6. Boudin et al.: Primary Synovial Sarcoma of the Thyroid Gland: Case Report and Review of the Literature. *Case Rep Oncol* 2014;7:6-13. | 7. Chan JA, McMenamin ME, Fletcher CD. Synovial sarcoma in older patients: clinicopathological analysis of 32 cases with emphasis on unusual histological features. *Histopathology*. 2003 Jul;43(1):72-83. | 8. Dei Tos AP, Dal Cin P, Sciot R, Furlanetto A, Da Mosto MC, Giannini C, et al. Synovial sarcoma of the larynx and hypopharynx. *Ann Otol Rhinol Laryngol*. 1998 Dec;107(12):1080-5. | 9. Kikuchi I, Anbo J, Nakamura S, Sugai T, Sasou S, Yamamoto M, Oda Y, Shiratsuchi H, Tsuneyoshi M. Synovial sarcoma of the thyroid. Report of a case with aspiration cytology findings and gene analysis. *Acta Cytol* 2003; 47: 495-500. | 10. Alberty J, Dockhorn-Dworniczak B. Monophasic synovial sarcoma of the neck in an 8-year-old girl resembling a thyroglossal duct cyst. *Int J Pediatr Otorhinolaryngol*. 2002 Mar 15;63(1):61-5. | 11. Coindre JM, Pelmus M, Hostein I, Lussan C, Bui BN, Guillou L. Should molecular testing be required for diagnosing synovial sarcoma? A prospective study of 204 cases. | 12. Fisher C, de Bruijn DR, van Kessel AG. Synovial sarcoma. In: Fletcher CD, Unni KK, Mertens F, editors. *Pathology and genetics of tumors of soft tissue and bone*. Lyon: IARC Press; 2002. p. 200-4. | 13. Ryu CH, Cho KJ, Choi SH: Synovial sarcoma of the thyroid gland. *Clin Exp Otorhinolaryngol* 2011;4:204-206. | 14. Jang KS, Min KW, Jang SH, Paik SS, Tae K, Jang SJ, et al: Primary synovial sarcoma of the thyroid gland. *J Korean Med Sci* 2007;22:154-158. | 15. Ghatfoury A, Anbara T, Mir A, Lashkari M, Nazari M: Thyroid synovial sarcoma: a case report. *Acta Med Iran* 2013;51:69-72.