

Boerhaave's syndrome: a case report.



Medical Science

KEYWORDS: Boerhaave's syndrome, chest drainage, enterostomy, total parenteral nutrition.

Dr. Fahim Rajiwate	Department Of Surgery, MGM Medical College and Hospital, Kamothe, Navi Mumbai, Maharashtra – 410209
Dr. Ashok Kalyanshetti	Professor, Department Of Surgery, MGM Medical College and Hospital, Kamothe, Navi Mumbai, Maharashtra
Dr. Ashish Jadhav	Assistant Professor Department Of Surgery, MGM Medical College and Hospital, Kamothe, Navi Mumbai, Maharashtra

ABSTRACT

Boerhaave's syndrome or spontaneous oesophageal perforation, is a potentially lethal and frequently elusive medical condition which presents not only a diagnostic but also a therapeutic challenge. It is insufficiently considered in diagnostic hypotheses, yet may be confirmed or excluded by simple methods such as an erect chest film and a contrast study of the oesophagus. Errors in diagnosis are usually caused by unawareness of its varied and atypical presentations or failure to consider its possibility in acute cardiothoracic and upper gastrointestinal conditions. Early aggressive surgical intervention in the form of open and wide mediastinal and chest drainage, with or without oesophageal repair, resection or exclusion, offers the patient the best chance of survival against this otherwise invariably fatal event. Nonoperative therapy consisting of antibiotics, nil oral regimen, nasogastric tube suction, pleural drainage, H2 receptor blockers and either a feeding enterostomy or total parenteral nutrition, may also be appropriate in selected patients. It is probable that the condition is more common than is generally supposed. All clinicians need to be aware of this lethal disease, its frequently unusual presentations and the importance of early diagnosis.

introduction

Boerhaave's syndrome is rupture of the oesophageal wall. 56% of oesophageal perforations are iatrogenic, usually due to medical instrumentation such as an endoscopy or paraoesophageal surgery. In contrast, the term Boerhaave's syndrome is reserved for the 10% of oesophageal perforations which occur due to vomiting. Spontaneous perforation of the oesophagus most commonly results from a sudden increase in intraoesophageal pressure combined with relatively negative intrathoracic pressure caused by straining or vomiting (effort rupture of the oesophagus or Boerhaave's syndrome). Other causes of spontaneous perforation include caustic ingestion, pill oesophagitis, Barrett's oesophagus, infectious ulcers in patients with AIDS, and following dilation of oesophageal strictures.

In most cases of Boerhaave's syndrome, the tear occurs at the left postero-lateral aspect of the distal oesophagus and extends

for several centimeters. The condition is associated with high morbidity and mortality and is fatal in the absence of therapy. The occasionally nonspecific nature of the symptoms may contribute to a delay in diagnosis and a poor outcome. Spontaneous effort rupture of the cervical oesophagus, leading to localized cervical perforation, may be more common than previously recognized and has a generally benign course. Preexisting oesophageal disease is not a prerequisite for esophageal perforation but it contributes to increased mortality. This condition was first documented by the 18th-century physician Herman Boerhaave, after whom it is named

Case Details

A 18 year male presented to casualty with chief complaints of acute onset of breathlessness and chest pain following a bout of alcohol. He was transferred from primary centre with preliminary treatment of ICD insertion.

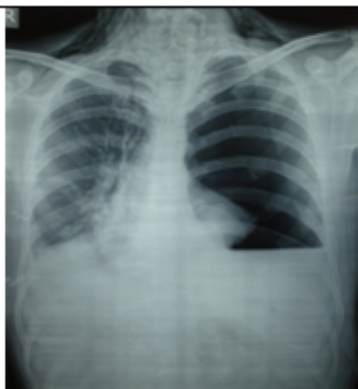

fig 1: CXR showing pneumothorax with subcutaneous emphysema.

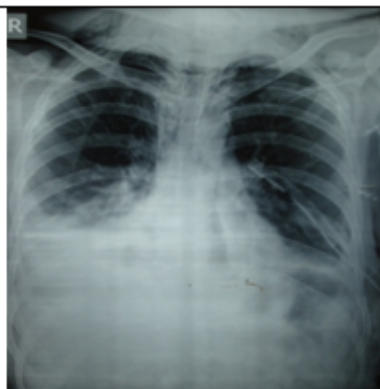

fig-2: CXR post ICD insertion.

On presentation, the patient was in mild respiratory distress with a respiratory rate of 30 breaths/min, a heart rate of 90 beats/min, and an oxygen saturation measured via pulse oximetry of 93% while breathing room air. A respiratory examination revealed the left-sided findings of reduced chest expansion, hyper resonance to percussion, and reduced air entry. Patient was referred from primary centre with preliminary treatment of

ICD insertion. A chest radiogram revealed large left hydropneumothorax left with subcutaneous emphysema in upper thorax, total collapse of left lung, surgical emphysema in neck, mediastinum shift to right, Right lung normal. The ICD was draining serous fluid with no air column movement. Hence a contrast tomography was performed which showed ICD insertion through the 8th intercostal space, peritoneum, diaphragm into

left pleural space. Followed by which an ICD was inserted in left 6th intercostal space. Post ICD insertion radiogram showed expansion of left lung with clear left costo-phrenic angle, Cardiac shadows and mediastinum appears normal and blunting of right costo-phrenic angle.

Patient was stabilized and an Oesophagogastrosomy was performed which showed full thickness mallory weiss tear extending 1 inch proximally from cardioesophageal junction with devitalised mucosa and margins with gap of 1 mm with no active bleed from the tear. Patient was then managed by NPO, Ryles Tube insertion Gastrostomy and feeding jejunostomy. During the course a right ICD was inserted for right pleural effusion.

Methylene Blue dye (diluted) was given per orally to determine the patency of oesophagus at regular intervals which showed dye in left under water seal bag which eventually stopped. Confirmation in form of gastrograffin studies were done which showed normal patency of oesophagus. Patient tolerated per orally with removal of gastrostomy and jejunostomy.

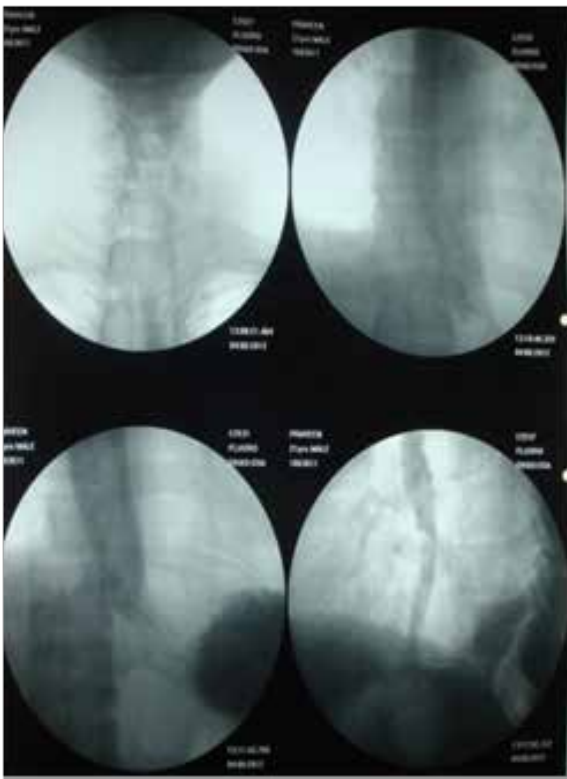


fig 3: Gastrograffin Study

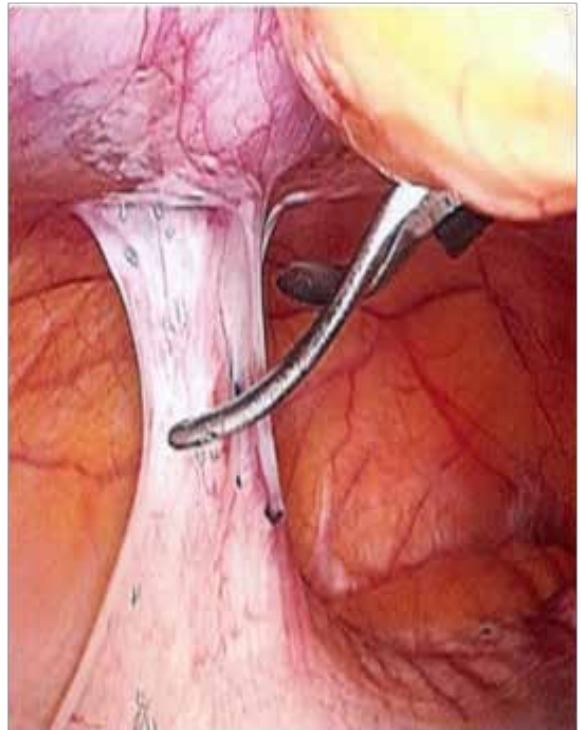


fig 4:Diagnostic laparoscopy finding-adhesion

After some days patient developed signs of intestinal obstruction for which diagnostic laparoscopy was performed which showed adhesion between anterior abdominal wall and loop of jejunum resulting in kinking of the jejunal loop. Adhesion band was cut. Postoperatively the patient made excellent progress and was weaned to a normal diet over a period of a month.

Discussion

The Spontaneous oesophageal rupture was originally described by Herman Boerhaave in 1724 . It typically occurs in men aged 30-40 years after over indulgence in alcohol or food; but may result from any emetogenic pathology. It must be distinguished from the more common traumatic oesophageal rupture and pathological oesophageal rupture. In Boerhaave's syndrome, the oesophagus undergoes barotrauma when increased intra-gastric pressure is transmitted to the oesophagus against a closed glottis . The classical presentation is Mackler's triad, which comprises thoraco-abdominal pain, vomiting and surgical emphysema. Diagnosis of Boerhaave's syndrome can often be a clinical challenge. The single most important factor is a high index of clinical suspicion. Blood investigations are of limited diagnostic use. A convincing history, suggestive clinical findings and radiological imaging were sufficient to diagnose Boerhaave's in this case .

REFERENCE

1. Brauer RB, Liebermann-Meffert D, Stein HJ, Bartels H, Siewert JR: Boerhaave's syndrome: analysis of the literature and report of 18 new cases. *Dis Esophagus* 1997, 10:64-68. | 2. Sabanathan S, Eng J, Richardson J: Surgical Management of intrathoracic Oesophageal rupture. *Br J Surg* 1984, 81:863-865 | 3. Long CM, Ezenkwele UA: Oesophageal perforation, rupture and tears. | 4. Abbot A: Atraumatic so-called spontaneous rupture of the esophagus. *Jou Thorac Cardiovasc Surg* 1970, 59:67. | 5. Ghanem N, Altheoefer C, Springer O, Furtwangler A, Kotter E, Schafer O, Langer M: Radiological findings in Boerhaave's syndrome. *Emerg Radiol* 2003, 10:8-13. | 6. Pate JW, Walker WA, Cole FH, Owen EW, Johnson WH: Spontaneous rupture of the oesophagus: a 30-year experience. *Ann Thorac Surg* 1989, 5:689-692. | 7. Curci J, Horman J: Boerhaave's syndrome: The importance of early diagnosis and treatment. *Ann Surg* 1976, 183:401-408. | 8. Korn O, Onate JC, Lopez R. Anatomy of the Boerhaave syndrome. *Surgery*. Feb 2007;141(2):222-8. | 9. Datta CK, Brannon JV. Spontaneous rupture of esophagus (Boerhaave syndrome): a review of literature and a case presentation. *W V Med J*. Jul 1979;75(7):180-2. | 10. Janjua KJ. Boerhaave's syndrome. *Postgrad Med J*. May 1997;73(859):265-70. | 11. White RK, Morris DM. Diagnosis and management of esophageal perforations. *Am Surg*. Feb 1992;58(2):112-9. | 12. Smyth AR, Wastell C. Spontaneous rupture of the oesophagus (Boerhaave's syndrome): delayed diagnosis and successful conservative management. *J R Soc Med*. Aug 1989;82(8):498. | 13. Zawisza MJ, Geisler A. Spontaneous rupture of esophagus (Boerhaave's syndrome): case report and literature review. *J Am Osteopath Assoc*. Jun 1988;88(6):787-90. | 14. Salim AS. Jejunostomy feeding for the conservative management of spontaneous rupture of the oesophagus. *Br J Clin Pract*. Spring 1991;45(1):37-40. |