



Orthopaedics

STUDY ON FUNCTIONAL OUTCOME OF DISTAL FEMUR FRACTURES USING RETROGRADE INTERLOCKING NAIL IN A TERTIARY CARE HOSPITAL

Begari Rohith	Assistant Professor,, GMC, Wanaparthy
G.rama Krishna	Assosiate Professor, GMC, Suryapet
M S Swaroop	M S Orthopaedics
Satish Parupalli*	Assosiate Professor , GMC , Sangareddy*Corresponding Author

ABSTRACT Distal femur fractures are associated with high energy trauma in younger individuals and trivial trauma in elderly patients. They constitute for 6% of the femoral fractures. The study aims to show surgical fixation of the fracture using supracondylar nail gives favourable results. **METHODS AND MATERIALS:** This study was done in Department of Orthopaedics and Traumatology in Osmania General Hospital, Hyderabad as a prospective study. Total number of cases are 30 during the period of January 2021 to July 2022. Supracondylar fractures were classified using AO and Class 33A were fixed using this method. **RESULTS :** Out of the 30 patients, 22 were male and 8 were female, with more than 50% of the patients less than 40 years. All the fractures were fixed with Retrograde Supracondylar interlocking nail. 18 Based on NEER's score 18 cases had excellent results while only 1 had poor outcome. 25 patients had full weight bearing by 24 weeks and 27 patients had knee flexion of more than 100° with minimal complications. **CONCLUSION:** Retrograde supracondylar interlocking nail is an optimal implant for supracondylar femur fractures (AO-33A) which is a minimally invasive technique with shorter surgical duration, hospital stay and infection risk and with early mobilization, recovery and with excellent results.

KEYWORDS : Distal femur, retrograde, inter locking

INTRODUCTION

Distal femur fractures are complicated injuries causing challenge to the orthopaedic surgeons. High energy trauma is the most common cause Of these fractures in the young individuals where as in elderly people mild trauma such as a simple fall can cause this fractures because of osteopenia.

Distal femur fractures are frequently associated with difficulty in reduction, loss of reduction even after surgical reduction, nonunion and malunion. So proper technique and implants are must for fixing these fractures.

n these fractures spasm and irritability of quadriceps, hamstrings and adductors causes limb shortening and varus angulation at fractures site. Gastrocnemius contraction produces an apex, posterior angulation and displacement of distal fragment. These forces should be overcome during fracture reduction and internal fixation must be strong in enough to prevent redisplacement.

Supracondylar retrograde interlocking nail's important advantage is it produces alignment of femoral shaft with condyles and decreases the tendency for varus displacement. It preserves fracture hematoma, deceases blood loss, minimizing soft tissue dissection and also have a lower infection rate.

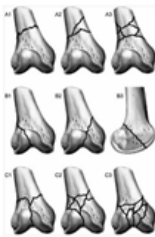


FIGURE 1: AO CLASSIFICATION OF SUPRACONYLAR FEMUR FRACTURES

Distal femur (33-points)		Proximal femur (33-points)	
A - Pattern (24-points)		B - Pattern (24-points)	
A1 - No comm.	24	B1 - No comm.	24
A2 - Minimally comm.	12	B2 - 1 degree angulation or 2 cm displacement	12
A3 - Lytic comm.	6	B3 - 2 degree angulation or 2 cm displacement	6
A4 - Comminuted or all comm.	0-6	B4 - Greater than 2 cm displacement, angulation	0
C - Working capacity (9-points)		D - Non union or chronic infection (9)	
C1 - Stable	9	D1 - Non union	9
C2 - Stable comm.	6	D2 - 1 degree angulation or 2 cm displacement	6
C3 - Unstable comm.	3	D3 - 2 degree angulation or 2 cm displacement	3
C4 - Unstable comm. or all comm.	0-3	D4 - 3 degree angulation or 2 cm displacement	0

Distal femur (33-points)		Proximal femur (33-points)	
A1 - No comm.	24	B1 - No comm.	24
A2 - Minimally comm.	12	B2 - 1 degree angulation or 2 cm displacement	12
A3 - Lytic comm.	6	B3 - 2 degree angulation or 2 cm displacement	6
A4 - Comminuted or all comm.	0-6	B4 - Greater than 2 cm displacement, angulation	0
C - Working capacity (9-points)		D - Non union or chronic infection (9)	
C1 - Stable	9	D1 - Non union	9
C2 - Stable comm.	6	D2 - 1 degree angulation or 2 cm displacement	6
C3 - Unstable comm.	3	D3 - 2 degree angulation or 2 cm displacement	3
C4 - Unstable comm. or all comm.	0-3	D4 - 3 degree angulation or 2 cm displacement	0

FIGURE-2 NEER'S SCORING SYSTEM

ExcellentMore than 85 points
 Good70 to 85 points
 Fair55 to 69 points
 PoorLess than 55 points

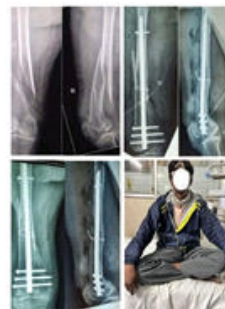

FIGURE-3 A.PRE-OP XRAY , B.IMMEDIATE POST-OP XRAY C. 6MONTHS POST-OP XRAY D.FUNCTIONAL ROM AT 6MONTHS

CASE STUDY

In the present study 30 patients of both sexes and ages above 18 years with Supracondylar femur fractures (type A1) willing to participate as study subjects were operated using retrograde interlocking nail and followed up for a period of 6 months using neer's scoring system. Out of 30 patients 18 patients had excellent results while 1 patient had poor outcome, 25 patients had full weight bearing by 24 weeks and 27 patients had knee flexion of more than 100 degrees with minimal complications.

CONCLUSIONS

We can say that retrograde intramedullary femur nail is the optimal implant for supracondylar fractures of the femur it provides rigid fixation in a region of femur where a wide canal, thin cortices and frequently poor bone stock make fixation difficult surgical exposure for nail placement requires significantly less periosteal stripping and soft tissue exposure than that of distal femur plates. Thus we can conclude that retrograde intramedullary supracondylar femur nail is a good fixation system for distal third femoral fractures, particularly A1 type (extraarticular)

REFERENCES:

- [1] Schatzker J, Tile M. The Rationale of Operative Fracture Care. Berlin: Springer, 1996
- [2] T. Neubaur, E.Ritter, T.Potschka, A Karlbauer, M Wagner 72 retrograde nailing of femoral fractures. Acta Chir Orthop Traumatol Cech June 2008
- [3] Watanabe Y, Takai S, Yamashita F, Kusakabe T. Second generation intramedullary supracondylar nail for distal femur fractures. International ortho (SICOT), 2002
- [4] Amrstrong L, Milliren A, Schrantz W, Zeligler K. Retrograde interlocked intramedullary nailing of supracondylar distal femur fractures in an average 76 year old patient population. Orthopaedics, June 2003