



A RARE CASE REPORT OF UNCONTROLLED HYPERTENSION AND BILATERAL BASAL GANGLIA BLEED

Dr. Shameem Ahmed

Senior Consultant Neurosurgeon, Apollo Hospitals Guwahati

Dr. Deep Dutta

Consultant Neurosurgeon, Apollo Hospitals Guwahati

Dr. Abhigyan Borkotoky*

Neurosurgery Resident, Apollo Hospitals Guwahati*Corresponding Author

ABSTRACT **INTRODUCTION** Basal ganglia are a group of nuclei located deep within the brain, and associated with various functions, including motor control, cognition, emotion, and procedural learning. Spontaneous hemorrhage of the basal ganglia due to uncontrolled hypertension is mostly unilateral. Bilateral basal ganglia hemorrhage (BBGH) is a rare entity, and only a few case reports and series are being published. **CASE REPORT** We report a 37-year-old male patient with a past medical history of hypertension on irregular medications who was brought to the emergency department with altered sensorium and slurring of speech. A non-contrast brain CT done in a local hospital showed a right BG Bleed. Upon Admission, we repeated the CT Brain, which showed Bilateral Basal Ganglia Bleed. His blood pressure was 220/120. The patient was admitted to the Neuro ICU and intravenous antihypertensives as well as antiedema medications were started. After clinical improvement, he was shifted to the ward on the fifth day and after that was referred to a rehabilitation center. **CONCLUSION** Bilateral Basal Ganglia Hemorrhage (BBGH) is a rare disease entity. Given the infrequency of BBGH, it is especially noteworthy to report a compelling case involving a patient having simultaneous spontaneous bilateral basal ganglia hemorrhage secondary to uncontrolled hypertension.

KEYWORDS : Uncontrolled hypertension, bilateral basal ganglia, hemorrhagic stroke, Rare, Bilateral

INTRODUCTION

The definition given for Intracerebral hemorrhage (ICH) by the American Stroke Association (ASA) states that ICH is "Rapidly developing clinical signs of neurological dysfunction attributable to a focal collection of blood within the brain parenchyma and/or ventricular system which is not due to trauma". In the majority of cases, the bleeding is usually solitary and unilateral and a few of the cases have multiple ICH and are bilateral bilateral. Although Spontaneous Simultaneous Bilateral Basal Ganglia Hemorrhage (SSBBGH) is extremely rare, sporadic cases have been reported across the world. The mechanisms behind simultaneous bilateral basal ganglia bleed are not thoroughly understood. Proposed factors include direct thermal effects from electrical currents, electrolytic effects induced by currents, physical trauma from lightning, and acute severe hypertension triggered by abrupt peripheral vascular contraction.

CASE PRESENTATION

A 37-year-old male patient presented to our emergency department with a history of slurring of speech and altered sensorium for the last 8 hours along with weakness of the right side of the body. He complained of severe headaches as well. He was initially treated at a local hospital where he received a bolus dose of mannitol and was referred to our institute for further management. A CT Head done at the local hospital showed a right basal ganglia bleed. Upon detailed history taking, he was diagnosed case of hypertension 2 years back for which he was prescribed antihypertensive medications but after 2-3 months of regular usage, his drug intake became irregular. The patient after initial stabilization at ED was admitted to Neuro ICU and closely monitored. Infusion labetalol had to be started as his BP had gone up to 200/110mmHg. After about 3-4 hours post-admission, the sensorium of the patient started deteriorating so a repeat CT head was done. CT Head showed hyper-densities in bilateral Basal ganglia with mass effect. A CT Angiogram was also done in the same setting which was negative. Angioedema measures were escalated and the patient was intubated given the deteriorating sensorium. A decision on ICP monitoring was planned. Bedside, we inserted an intraparenchymal ICP transducer and the reading fluctuated between 22-26mmHg. But despite all the efforts, the ICP remained above 20mmHg. So, a decision of bifrontal Decompressive craniectomy was planned. The patient after the procedure was shifted back to Neuro ICU and closely monitored. Weaning off was started from POD 1. But despite multiple attempts, there was a weaning failure so we decided to go ahead with percutaneous tracheostomy on POD 4. Post-tracheostomy slow weaning was tried and the patient was eventually disconnected from the ventilator on POD 8. Gradually the sensorium of the patient improved and he was obeying simple commands although he had

quadriparesis. Daily physiotherapy and mobilization were carried out. By POD 12 he was shifted out of ICU to the wards and on POD 15 he was shifted to a rehabilitation centre. The patient was on regular follow-up. His BP was well controlled with the proper titration of drugs and his limb power had improved to 3/5 bilaterally. After 6 weeks he was admitted again for autologous cranioplasty. He was fully oriented to time, place, and person on admission. After preoperative optimization, the patient underwent cranioplasty. The operative procedure was uneventful and 2 weeks post cranioplasty we were able to decannulate him. The patient made a good functional recovery and is now able to walk with support.

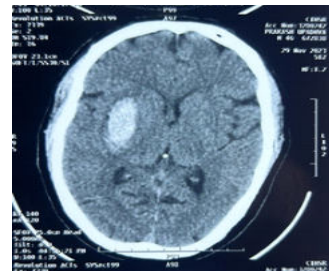


Figure 1: CT Head of patient done 4 hours after Ictus showing a hyperdensity in the right Gangliocapsular region

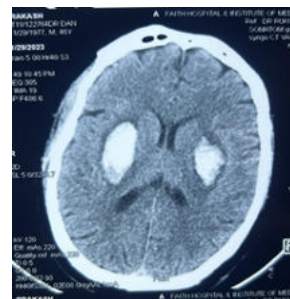


Figure 2: CT Head of patient done 10 hours after Ictus showing bilateral hyperdensity in the Gangliocapsular region

DISCUSSION

Bilateral basal ganglia hemorrhages have been associated with various factors such as trauma, methanol poisoning, diabetic ketoacidosis, hyperglycaemic hyperosmolar syndrome, lightning, uncontrolled hypertension, anticoagulant use, and fungal infection. (4) (5) The

patient's medical history revealed only uncontrolled hypertension, with poor compliance to prescribed medication. There were no indications of trauma, coagulopathy, diabetes, or infections. Hypertension was deemed the likely underlying cause, given the absence of other identified etiologies or risk factors. Additionally, the location of the hematoma aligned with patterns commonly observed in hypertension-related intracerebral hemorrhage. The exact etiopathogenesis of simultaneous bilateral basal ganglia hemorrhage in this scenario remains uncertain. Several hypotheses have been proposed by various authors regarding this specific context.

The most frequently suggested pathogenesis involves the coincidental rupture of bilateral microaneurysms on lenticulostriate arteries. Alternatively, some mechanisms propose that the initial hemorrhage creates a specific hemodynamic environment, triggering a reflex increase in blood pressure and causing the rupture of a second microaneurysm on the contralateral side within a brief period, a scenario deemed more plausible. (6) Spontaneous hemorrhage occurs when a sudden surge in blood pressure, triggered by emotional or physical strain, leads to the rupture of the lenticulostriate artery, resulting in the formation of a hematoma. The underlying causes of this situation often include congenital vascular malformation, prolonged hypertension, and diabetes mellitus. (7)

The basal ganglia and thalami represent highly metabolic regions of the brain, rendering them vulnerable to hypoxic-ischemic injury, toxic poisoning (carbon monoxide, methanol, and cyanide), metabolic abnormalities (Hypoglycaemia, Leigh disease, hepatic disease, Wilson disease, and osmotic myelinolysis), and neurodegeneration. Additionally, bilateral basal ganglia or thalami can be affected by focal flavivirus infection, toxoplasmosis, and primary central nervous system lymphoma. (7) There is also a theoretical proposition that the etiopathology of COVID-19, whether through direct invasion or systemic inflammatory responses, might play a role in the occurrence of bilateral basal ganglia hemorrhage and subsequent neurological deficits. (9)

As involving the bilateral basal ganglia is exceptionally severe, a grim outcome is consistently expected. Consequently, a debate emerges regarding the advisability of surgical intervention for the patient. Given the destruction of both crossing and non-crossing fibers, the occurrence of bilateral diaschisis phenomenon, significantly impaired and altered levels of consciousness, quadriplegia, and pseudobulbar palsy, compromised aftermath is carefully considered. (10) Divergent opinions exist among professionals regarding the optimal approach to hematoma evacuation. Some advocate for immediate evacuation based on the hematoma's volume, while others prefer a more cautious stance, opting to perform surgery only when there are discernible signs of increased intracranial pressure.

Our patient underwent Decompressive craniectomy without hematoma evacuation and fortunately, he made a commendable recovery. It is noteworthy that, his neurological function improved, rendering him a self-sufficient individual.

CONCLUSION

Bilateral Basal Ganglia Hemorrhage (BBGH) is a rare event that can be linked to a diverse range of traumatic, vascular, chemical, infectious, and endocrinologic factors. Despite numerous hypotheses proposed by experts, the exact pathophysiological mechanisms driving its development remain a matter of debate. The management typically aligns with current Intracerebral Hemorrhage (ICH) guidelines, emphasizing supportive care and early blood pressure control as primary treatment modalities. While minimally invasive surgery shows promise in comparison to unilateral cases of hemorrhage, there is a need for stronger evidence supporting surgical intervention. Bifrontal decompressive craniectomy may be required for BBGH patients presenting with mass effect in whom medical therapy fails to achieve optimal control of ICP. However, future studies and trials in this field should carefully consider the specific hemorrhage location, dominance of the injured hemisphere, and associated risks related to surgical interventions.

REFERENCES

1. Sacco RL, Kasner SE, Broderick JP, Caplan LR, Connors JJ, Culebras A, Elkind MS, George MG, Hamdan AD, Higashida RT, Hoh BL, Janis LS, Kase CS, Kleindorfer DO, Lee JM, Moseley ME, Peterson ED, Turan TN, Valderrama AL, Vinters HV. American Heart Association Stroke Council, Council on Cardiovascular Surgery and Anesthesia; Council on Cardiovascular Radiology and Intervention; Council on Cardiovascular and Stroke Nursing; Council on Epidemiology and Prevention; Council on Peripheral.

- Stroke. 2013 July; 44(7): p. 2064-89.
2. Alhashim A, Hadhiah K, Al-Dandan H, Aljaman M, Alabdali M, Alshurem M, Aljaafari D, AlQarni M. Spontaneous Simultaneous Bilateral Basal Ganglia Hemorrhage (SSBBGH): Systematic Review and Data Analysis on Epidemiology, Clinical Feature, Location of Bleeding, Etiology, Therapeutic Intervention and Outcome. *Vasc Health Risk Manag.* 2022 April; 18: p. 267-276.
3. Stanley LD, Suss RA. Intracerebral hematoma secondary to lightning stroke: case report and review of the literature. *Neurosurgery.* 1985 May; 16(5): p. 686-8.
4. ato M, Tanaka S, Kohama A, Sone T, Fukunaga M, Morita R. Spontaneous bilateral intracerebral hemorrhage occurring simultaneously case report. *Neurol Med Chir.* 1986; 7(26): p. 545-547.
5. Verma A. Bilateral basal ganglionic hemorrhage. *Arch Neurol.* 2006; 3(63): p. 464.
6. Zhao J, Chen Z, Wang Z, Yu Q, Yang W. Simultaneous bilateral hypertensive basal ganglia hemorrhage. *Neurol Neurochir Pol.* 2016; 4(50): p. 275-279.
7. Zhang YX, Wei SQ, Xing YY, Liu Q, He WJ. Bilateral traumatic hemorrhage of the basal ganglia. *Chinese J Traumatol.* English Ed. 2016; 4(19): p. 247-248.
8. Hegde AN, Mohan S, Lath N, Lim CCT. Differential diagnosis for bilateral abnormalities of the basal ganglia and thalamus. *Radiographics.* 2011; 1(31): p. 5-30.
9. Daci R, Kennelly M, Ferris A, Azeem MU, Johnson MD, Hamzei-Sichani F, Jun-O'Connell AH, Natarajan SK. Bilateral Basal Ganglia Hemorrhage in a Patient with Confirmed COVID-19. *AJNR Am J Neuroradiol.* 2020 October; 10(41): p. 1797-1799.
10. Yen CP, Lin CL, Kwan AL, Lieu AS, Hwang SL, Lin CN, Howng SL. Simultaneous multiple hypertensive intracerebral hemorrhages. *Acta Neurochir (Wien).* 2005 April; 4(147): p. 393-9.