



## FREE GINGIVAL GRAFT: ENHANCING AESTHETIC AND FUNCTIONAL OUTCOMES IN PERIODONTAL TREATMENT – A CASE SERIES

<b>Dr. Vishrut Mehta</b>	PG student.
<b>Dr. Pallavi Mahavadiya*</b>	PG student. *Corresponding Author
<b>Dr. Rahul Shah</b>	Professor.
<b>Dr. Anita Panchal</b>	Professor & Head of Department.

### ABSTRACT

Gingival recession is defined as the Displacement of soft tissue margin apical to the cemento-enamel junction. Free gingival grafts (FGG) are employed in periodontal treatment to increase the amount of attached gingiva and cover exposed root surfaces. This article reviews the effects of FGG in three patients lacking sufficient keratinized gingiva, aiming to enhance periodontal stability by increasing the width of attached gingiva. The case series emphasizes specific procedural details, such as the choice and preparation of the donor site, graft harvesting, and postoperative care. Results show a notable improvement in the width of keratinized tissue, tissue quality, and patient satisfaction with aesthetic, functional aspects and maintenance of soft tissue.

**KEYWORDS :** Free gingival graft, Gingival recession, Root coverage

### INTRODUCTION:

Gingival recession is defined as Displacement of soft tissue margin apical to the cemento-enamel junction.<sup>1</sup> Major causes for gingival recession include plaque induced periodontal disease, mechanical force such as faulty tooth brushing technique, iatrogenic factors like orthodontic movements, faulty restorations and anatomic factors such as malposition, frenum pull and buccally placed roots etc.<sup>2</sup> It is associated with functional problems such as dentinal hypersensitivity, root caries, cervical abrasion, difficult maintenance of oral hygiene and compromised aesthetics.

There are various surgical techniques available for root coverage like rotational flaps, coronally advanced flap, free gingival graft, guided tissue regeneration, connective tissue graft and combination of these. Despite of advances in techniques of correction of gingival recession, free gingival graft continues to be a reliable procedure for increasing the width of keratinized gingiva and stopping the progression of gingival recession as it shows high predictability in terms of graft survival and postsurgical tissue stability along with being simple, multiple teeth can be treated at once, easy tissue handling, and can be performed when keratinized gingiva adjacent to involved teeth is insufficient.<sup>3</sup>

In these cases, free gingival graft was chosen as the procedure to be followed.

### CASE REPORTS:

#### CASE 1:

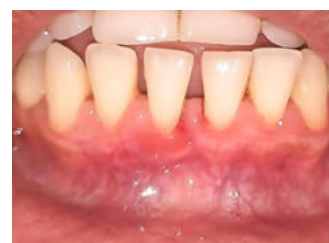A 33-year-old female patient reported to the Department of Periodontology, College of Dental Sciences and research centre, India with a chief complaint of receding gums and sensitivity in the lower front tooth. On examination, gingival recession was observed in the region of 41 and it was diagnosed as class II gingival recession based on Miller's classification (1986). Presurgical therapy included patient education and motivation, scaling and root planing with plaque control instructions. The patient was scheduled to undergo mucogingival surgery. The procedure was explained to the patient and informed written consent was obtained.

The exposed root surface was carefully scaled and root planed. After adequate local anesthetic application, A 3-4 mm wide recipient connective tissue bed was prepared apical and lateral to the recession defect. The area was demarcated by first placing a horizontal incision, at the level of the CEJ, in the

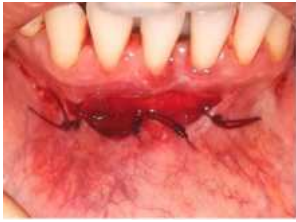interdental tissue on each side of the tooth to be treated. Subsequently, two vertical incisions, extending from the incision line placed in the interdental tissue to a level approximately 4-5 mm apical to the recession, were placed. A horizontal incision was then made connecting the two vertical incisions at their apical termination. Starting from an intracrevicular incision, a split incision was made to sharply dissect the epithelium and the outer portion of the connective tissue within the demarcated area.

The amount of donor tissue needed was accurately determined by using a foil template. A tin foil template of the recipient site was prepared. The palatal site between premolars and the first molar was selected to harvest the donor tissue using the conventional technique. The initial incisions were outlined by the placement of tinfoil template with a no. 15C scalpel blade. Care was taken to place the incision 2 mm away from the palatal gingival margin to prevent recession on these teeth. Incisions were made in such a fashion as to create the butt joint margin in the donor tissue. The incision was made along the occlusal aspect of the palate with no. 15C scalpel blade held parallel to the tissue, continued apically, lifting and separating the graft. Tissue pliers were used to retract the graft distally as it was being separated apically and dissected, until the graft was totally freed. An epithelised free gingival graft with a 2-3 mm thickness was dissected from the donor area. The graft obtained was inspected for any glandular or fatty tissue remnants. The graft was placed on the recipient bed and suture by means of interrupted sutures at the coronal and apical borders. A holding sutures were given for close adaption of the graft to the tooth surface. After suturing a periodontal pack was placed to protect the surgical site. The palatal wound was protected by a Hawley's retainer.

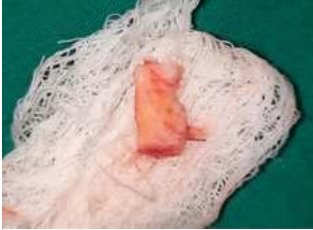### Figures:



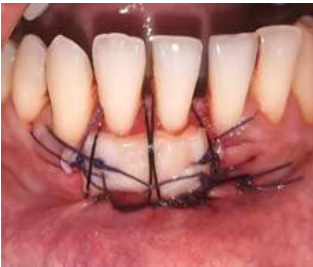**Figure 1:** Pre operative view



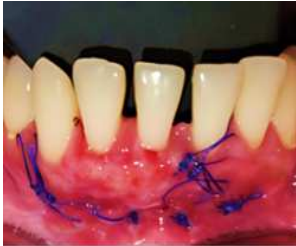**Figure 2:** Vestibular extension done and Recipient bed prepared



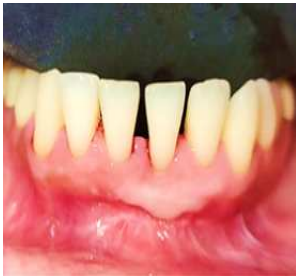**Figure 3:** Free gingival graft



**Figure 4:** Suturing the graft to the recipient bed



**Figure 5:** Healing after 7 days

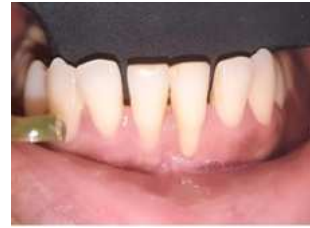

**Figure 6:** Healing after 1 month

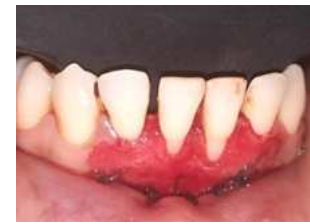**CASE 2:**

A 29-year-old female patient reported to the Department of Periodontology with a chief complaint of root surface exposure in the lower front tooth region which was esthetically unpleasant. The patient's medical and dental history was not significant. Intraoral examination revealed class II gingival recession based on Miller's classification (1986) in relation to 31 and 41. The oral hygiene status was good. Presurgical therapy included patient education and motivation, scaling and root planing with plaque control instructions. The aim of the treatment was to create an adequate band of attached, keratinized tissue at 31 and 41. Free gingival graft was selected as the treatment of choice because it was achieve all these goals in one surgery, in addition to the possibility of covering the roots through creeping attachment overtime.

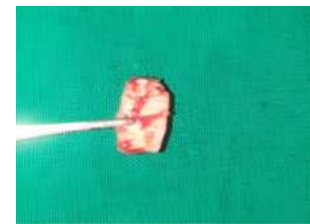**Figures:**



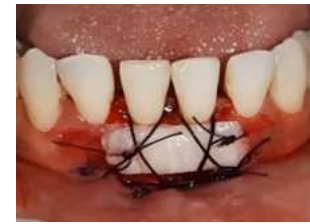**Figure 7:** Pre operative view



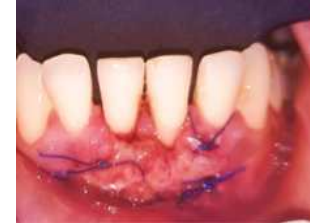**Figure 8:** Vestibular extension done and Recipient bed prepared



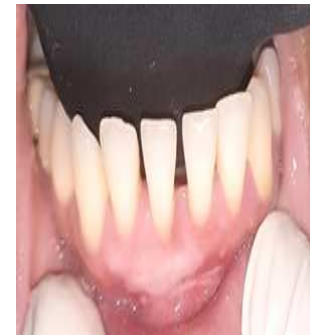**Figure 9:** Free Gingival graft



**Figure 10:** Suturing the graft to the recipient bed



**Figure 11:** healing after 7 days



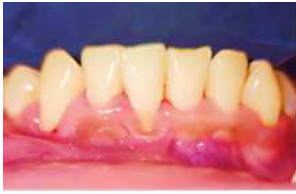**Figure 12:** healing after 1 month

**CASE 3:**

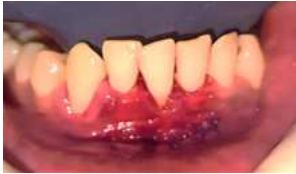A 25 year old male patient reported to the Department of Periodontology with the chief complaint of root sensitivity and receding gum in lower front tooth region. Intraoral clinical examination revealed class II gingival recession based on

Miller's classification (1986) on 41. Phase I therapy was carried out and One step technique of FGG to achieve recession coverage was planned. The procedure was explained to the patient and an informed written consent was obtained for surgery.

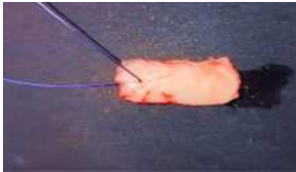
**FIGURES:**



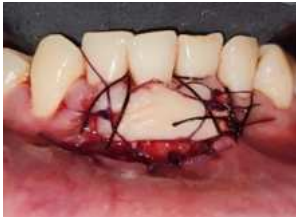**Figure 13:** Pre operative view



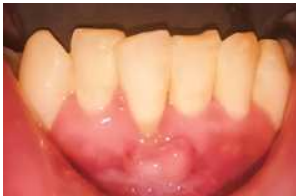**Figure 14:** Vestibular extension done and recipient bed prepared



**Figure 15:** Free gingival graft



**Figure 16:** Suturing the graft to the recipient bed



**Figure 17:** Healing after 1 month

The same surgical procedure, as mentioned above, was employed in all these cases.

**Post Operative Instructions:**

The patient was asked avoid spitting for the first 24 hours as this can dislodge the blood clot, delay healing, and increase the risk of bleeding. After that, oral hygiene instructions included mouth rinses with 10 ml of 0.2% chlorhexidine digluconate mouthwash twice daily for 1 minute for 2 weeks and a course of antibiotics and analgesics was prescribed (amoxicillin 500 mg and Diclofenac Sodium paracetamol 375 mg thrice daily for 5 days). The patient was instructed to wear the Hawley's appliance continuously for the first five days after surgery. After that, the appliance should only be worn while eating. Patient was also asked to refrain from tooth brushing at the surgical site for 10 days. The pack was removed 10 days postoperatively. The surgical site was irrigated with normal saline and sutures were removed. The healing of palatal wound was satisfactory. The patient was instructed to use a soft bristled toothbrush followed by a 30 seconds rinse with

chlorhexidine digluconate for the next 6 weeks.

The case was followed up every month and re-evaluated.

**DISCUSSION:**

Free gingival graft is a versatile mode of treatment which can be used to cover denuded roots and to increase the width of attached gingiva. FGG were initially described by Bjorn in 1963.<sup>4</sup> The term FGG was first suggested by Nabers.<sup>5</sup> Since then, they have been used not only to cover denuded root surfaces; but also to increase the width and thickness of attached gingiva. Root coverage by placing free graft was described by Sullivan and Atkins in 1968 and they reported that free gingival graft offers best results in cases of shallow and narrow recession.<sup>6</sup> Later Miller (1985)<sup>7</sup> described a useful classification of recession defects taking into consideration the anticipated root coverage that is possible to obtain.

Gingival recession usually creates an esthetic problem and fear of tooth loss due to progressive destruction, and may also be associated with dentin hypersensitivity, root caries and/or cervical wear. The treatment of gingival recession is mainly aimed to attain a wide band of keratinized gingiva which will provide better plaque control and lead to a possible significant improvement of the periodontal attachment apparatus.<sup>8</sup> The effective management of gingival recession hinges on identifying and addressing its causative factors, assessing the extent of tissue involvement, and meticulously choosing and executing the right surgical technique to achieve the best possible root coverage, enhanced soft tissue aesthetics and diminished sensitivity.<sup>9</sup>

The surgical options currently available for root coverage include free epithelialized gingival grafts, subepithelial connective tissue grafts, semilunar flaps, coronally advanced flaps, and guided tissue regeneration. Each of these methods can be selected based on the specific needs of the case to optimize treatment outcomes.<sup>10</sup>

The connective tissue graft with coronally advanced flap is considered the gold standard technique in treatment of gingival recessions. Camargo et al. (2001)<sup>2</sup> recommended using a free gingival graft in situations where there is a shallow vestibular depth and frenal pull over the use of a subepithelial connective tissue graft.

At present, free gingival graft is lagging behind the connective tissue graft but it still holds an edge as far as simplicity and invasiveness of the procedure is concerned. Compared to other techniques, free gingival graft offers unpredictable results regarding colour match between donor tissue and recipient site, but studies regarding coverage of gingival recession with free gingival graft is lacking in Indian scenario where due to high melanin pigmentation better aesthetic results can be achieved with this procedure.<sup>11</sup>

Holbrook and Ochsenbein also used the free soft tissue autograft as a one step surgical procedure on 50 documented teeth and reported recession of less than 3 mm had 95.5% total root coverage, recession of 3 to 5 mm had coverage of 80% and recession more than 5 mm had 76% coverage.<sup>11</sup>

Miller in 1987 has proposed many factors for incomplete or failure of root coverage. These include improper classification of marginal tissue recession, inadequate root planning, improper root biomodification, improper preparation of recipient site, inadequate graft size and thickness, dehydration of graft, inadequate adaptation of graft to root and remaining periosteal bed, failure to stabilize the graft, excess or prolonged pressure in captions of sutured graft, reduction of inflammation prior to grafting, trauma to graft during initial healing.<sup>10</sup>

Close attention to proper diagnosis and the steps involved in the surgical procedure are crucial in maximizing the predictability of the free gingival graft in correcting mucogingival problems and achieving root coverage. In these cases, there was a complete absence of keratinized tissue which renders any attempt at coronally advancing the tissues very risky. Moreover, in these cases when we consider the fact that the vestibule is shallow in addition to the pull from the frenum, it becomes clear that coronally advancing the tissues is not a suitable approach in this situation. Therefore, free gingival graft was the simplest and most predictable treatment option for these cases.

Moving forward, we should continue to strive for excellence and innovation in periodontology to ensure that every patient receives the most tailored and effective treatment available.

#### REFERENCES:

1. American Academy of Periodontology. (1992). *Glossary of periodontal terms* (3rd ed.). Chicago, IL: American Academy of Periodontology.
2. Camargo, P. M., Melnick, P. R., & Kenney, E. B. (2001). The use of free gingival grafts for aesthetic purposes. *Periodontology 2000*, 27, 72-96. <https://doi.org/10.1034/j.1600-0757.2001.027001072.x>
3. Bjorn, H. (1968). Free transplantation of gingival propria. *Svensk Tandläkare Tidskrift*, 22, 684-689.
4. Nabers, J. M. (1966). Free gingival grafts. *Periodontics*, 4(5), 243-245.
5. Lang, N. P., & Loe, H. (1972). The relationship between the width of keratinized gingiva and gingival health. *Journal of Periodontology*, 43(10), 623-627. <https://doi.org/10.1902/jop.1972.43.10.623>
6. Sullivan, H. C., & Atkins, J. H. (1968). Free autogenous gingival grafts. III. Utilization of grafts in the treatment of gingival recession. *Periodontics*, 6(4), 152-160.
7. Miller, P. D., Jr. (1985). A classification of marginal tissue recession. *International Journal of Periodontics and Restorative Dentistry*, 5(2), 8-13.
8. Dilsiz, A., & Aydin, T. (2010). Gingival recession associated with orthodontic treatment and root coverage. *Journal of Clinical and Experimental Dentistry*, 2(1), 30-33.
9. Bernimoulin, J. P., Lüscher, B., & Mühlemann, H. R. (1975). Coronally repositioned periodontal flap: Clinical evaluation after one year. *Journal of Clinical Periodontology*, 2(1), 1-13. <https://doi.org/10.1111/j.1600-051x.1975.tb01721.x>
10. Miller, P. D., Jr. (1987). Root coverage with the free gingival graft: Factors associated with incomplete coverage. *Journal of Periodontology*, 58(10), 674-681. <https://doi.org/10.1902/jop.1987.58.10.674>
11. Holbrook, T., & Ochsenbein, C. (1983). Complete coverage of the denuded root surface with a one-stage gingival graft. *International Journal of Periodontics and Restorative Dentistry*, 3(3), 8-27.