

## RELAPSE OF NMO NEGATIVE NEUROMYELITIS OPTICA SPECTRUM DISORDER IN A MIDDLE AGED INDIAN FEMALE-A CASE REPORT

Dr Ishana Gaur

Junior Resident Doctor, Department Of Medicine, BJ Medical College, Ahmedabad.

**ABSTRACT**

**Background:** Neuromyelitis Optica Spectrum Disorder (NMOSD) is a central nervous system inflammatory disease usually with a relapsing course, that has a particular predilection to cause Optic Neuritis and Longitudinally extensive Transverse Myelitis (LETM). Approximately 70% of cases are associated with antibodies to Aquaporin 4 immunoglobulin G (AQ4IG-G). **Case presentation:** A 45 year old female presented to Civil Hospital Ahmedabad with complain(s) of bilateral lower limb weakness, sub acute in onset, progressive in nature, complain of loss of touch and pain sensation in bilateral lower limbs, urinary incontinence, all since 10 days. She had a history of similar illness 9 year ago and a history of sudden onset painful loss of vision in left eye consistent with optic neuritis in one year ago. On Neurological examination, there was loss of sensation below nipples, lower limbs were 0, Deep Tendon reflex of bilateral lower limbs were exaggerated, Plantar were upwards bilaterally. **Labs:** Complete Blood count, Liver Function Tests, Renal Function Tests all were within normal range. Serum B12 was within normal range. ANA by Indirect Immuno fluorescence was negative. HIV was negative. On routine CSF examination, protein was 18 mg/dl, cells were 2/hpf. CSF showed no unique Oligoclonal bands. Serum Aquaporin 4 immunoglobulin G (AQ4IG-G) negative, Myelin Oligodendrocyte Glycoprotein (MOG) antibody negative. Fundus examination was normal. MRI dorsal spine was suggestive of Longitudinally Extensive Transverse Myelitis (LETM), from D2-D12 level with diffuse grey and white matter involvement, hyperintense on T2 and STIR. MRI brain was suggestive of chronic small vessel ischemic changes. Patient was diagnosed Acute Transverse Myelitis due to relapse of AQ4IG-G negative Neuromyelitis Optica Spectrum Disorder (NMOSD). She was started on high dose methylprednisolone and Plasma Exchange. The patient improved significantly after starting the treatment. She was discharged on oral steroids and Azathioprine. **Summary:** Relapses in NMOSD tend to be more severe and disabling. The recovery is often incomplete with incremental disability. It is very important to diagnose this disease early and distinguish it from Multiple Sclerosis (MS) because of a number of drugs used for MS are ineffective and potentially harmful for NMOSD. Management of NMOSD is directed for rescue treatment for acute attacks which includes combination of Plasma exchange and steroids and maintenance immune therapies.

**KEYWORDS :** Aquaporin 4 immunoglobulin G antibody (AQ4IG-G), Longitudinally Extensive Transverse Myelitis (LETM), optic neuritis (ON), Multiple Sclerosis (MS), Plasma Exchange (PLEX)

**BACKGROUND:**

Neuromyelitis Optica Spectrum Disorder (NMOSD) is a severe, inflammatory demyelinating disease of the central nervous system that selectively affects optic nerves and spinal cord. Early discrimination between multiple sclerosis (MS) and NMO is important, as optimum treatment for both diseases may differ considerably. In contrast to typical MS, clinical experience and case series suggest that NMO requires long term immunosuppressive therapy. Diagnostic criteria for NMO from 1999 have been revised in 2015 by International Panel for NMO diagnosis. A variety of encephalopathic presentations may occasionally be encountered in NMOSD patients like area postrema syndrome and brainstem syndrome. Our understanding of NMO has changed rapidly over the past decade, with inclusion of Aquaporin 4 immunoglobulin G (AQ4IG-G) seronegative patients and increased sensitivity of diagnosis and prompt treatment.

**CASE PRESENTATION:**

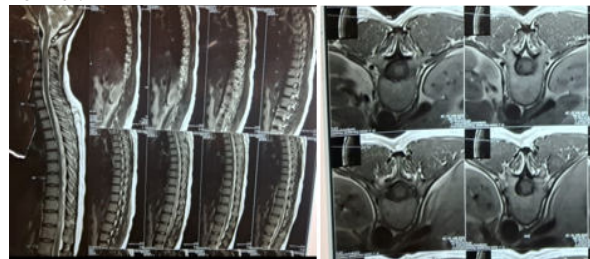
A 45 year old female presented to Civil Hospital Ahmedabad with complain(s) of loss of sensation in bilateral lower limbs, weakness in bilateral lower limbs and urinary incontinence, all since 10 days. There was no complain of fever, nausea, vomiting, headache, blurred vision, loss of consciousness or convulsion. Her complains were subacute in onset and progressive. She had a past history of similar complains 9 years ago and a history of sudden painful loss of vision in left eye one year ago. On general examination, she was vitally stable. She was conscious, cooperative and well oriented to time place and person.

Neurological examination - On sensory examination, there was decreased sensation below the nipples. Tone in all four limbs was normal. Power in bilateral upper limbs was +5 and in bilateral lower limbs was 0. Deep tendon reflexes in bilateral upper limbs were normal (+1). In bilateral lower

limbs, they were exaggerated (+3). Plantar were bilaterally extensor. Bladder and bowel sensation was absent. Gait and Romberg test were not elicitable. Cranial nerve examination, higher mental functions were normal. Pupils were normal in size and reactive to light. Rest of the neurological examination was normal.

**Blood tests:**

complete blood count, liver function test, renal function tests, serum B-12 were all within normal range. HIV was negative. Serum (AQ4IG-G) and MOG IgG were negative. Serum ANA by indirect immunofluorescence was negative. On examination of cerebrospinal fluid, there were 2 cells and protein was within normal range. There were no unique Oligoclonal Bands in CSF. Fundus examination was normal.

**Radiological Investigations:**

Current MRI brain was suggestive of chronic small vessel ischemic changes. MRI Spine was suggestive of long segment myelopathy (vertebral level D2- D12) with diffuse grey and white matter involvement of spinal cord. Lesions were hyperintense on T2 and STIR. Previous MRI done one year ago was suggestive of left sided optic neuritis involving two third length of optic nerve which was hyperintense on T2. MRI spine done 9 years ago was suggestive of changes of myelitis in lower Dorsal spinal cord (D9-L1) and upper central spinal cord (c2-c4). Lesions were hyperintense on T2 weighted MRI.

The patient was diagnosed with AQP4IG-G negative NMOSD and started on high dose corticosteroids (1 gram Methylprednisolone) for 7 days along with seven cycles of plasma exchange (PLEX) on alternative day. She gradually improved clinically. She was discharged on maintenance oral regimen containing Azathioprine and oral steroids.

#### DISCUSSION:

Neuromyelitis Optica Spectrum Disorder (NMOSD) is a family of diseases which is characterized predominantly by recurrent attacks of Optic Neuritis and Transverse Myelitis. It is closely related and often confused with Multiple Sclerosis (MS) with some major differences. Relapses in NMOSD tend to be more severe than MS and maybe fatal due to the involvement of cervical part of spinal cord leading to respiratory failure. Recent clinical criteria can distinguish between NMOSD and MS with higher sensitivity than before. Serum Aquaporin 4 Ig G (AQP4IG-G) is a highly specific marker for NMOSD found in around 70% of patients. Recently, a second antibody reactive to Myelin Oligodendrocyte Glycoprotein (MOG) has been found in 20-40% of AQP4IG-G negative patients. Roughly, around 10-20% of patients remain negative for both these biomarkers. The disease occurs worldwide with similar frequency of about 0.5-10/100000 population and disproportionate preponderance for females (female :male ratio of 8:1). It usually presents as relapsing attacks of Optic Neuritis and Transverse Myelitis. Other NMOSD spectrum syndromes include Area Postrema Syndrome, Diencephalic syndrome, Cerebral and Brain Stem Syndrome. Optic Neuritis in NMOSD typically presents as severe acute painful loss of vision in one or both eyes. Transverse myelitis presents with acute sensory, motor and sphincter impairments which are often severe and associated with involvement of central intramedullary spinal cord extending over 3 or more contiguous segments, commonly referred to as longitudinally extensive transverse myelitis (LEMS). Area postrema syndrome is characterized by intractable hiccups, vomiting and can occur in as many as 40% of patients of NMOSD during their disease course. Diencephalic syndromes include hypersomnolence, narcolepsy, anorexia, hyponatremia, hypothermia due to involvement of thalamus. Diagnosis of NMOSD relies on Clinical, Radiological and Laboratory features. Most recent diagnostic criteria were laid in 2015 by International Panel for NMO Diagnosis. It is classified further into two groups based on seropositivity for AQP4IG-G. Potential mimics of NMOSD should be excluded. Detection of (AQP4IG-G) is an integral part of diagnosis although the diagnosis can be made on clinical grounds. CSF examination is not a part of revised diagnostic criteria. CSF pleocytosis and absence of unique oligoclonal bands support the diagnosis of NMOSD. In AQP4IG-G negative patients, anti MOG Ig-G may be found in up to 40% of patients. 10-20% of patients remain double negative. Diagnosing NMOSD with reasonable accuracy and differentiating it from MS is very important from therapeutic and prognostic point of view. Many treatments commonly used in MS are either not useful or potentially harmful in patients of NMOSD. Management of NMOSD is targeted under two categories. One is treatment of acute attacks and other is initiation of maintenance immunosuppressive therapy for the prevention of relapses. NMOSD acute attacks are conventionally treated with a combination of high dose steroids and plasma exchange. Steroids are given in high dose (1 gm Methylprednisolone) for 5 to 7 days. Plasma exchange (PLEX) is used as adjunct to steroid because the attacks of NMOSD are typically more severe and do not respond to steroid therapy alone. In addition to that, plasmapheresis results in improvement up to 40% patients of NMOSD, who fail to respond to steroids. Plasma exchange is administered as five to seven cycles of approximately 1.5 times of plasma volume every other day. The efficacy of PLEX is found for both, seropositive and seronegative patients. For

maintenance therapy, many immunosuppressive drugs are currently available and approved for use in NMOSD. They can be started keeping in mind their availability, efficacy, cost benefit ratio, adverse effects and other patient factors. Rituximab (anti CD20) is an FDA approved drug for maintenance therapy in NMOSD. Other options are combination of either Azathioprine or Mycophenolate mofetil with oral steroids. Alternatives include inebilizumab, satralizumab, cyclophosphamide, and methotrexate. Mortality rates in NMOSD have improved over past couple years owing to prompt diagnosis and treatment. Although, the disease still remains to be a cause of severe residual disability. Younger age at onset and male gender are associated with greater visual disability and older age at onset is associated with great motor disability.

#### CONCLUSION:

Neuromyelitis optica spectrum disorder (NMOSD) is a Central nervous system disease which is characterized by relapsing courses of severe acute attacks of optic neuritis and long segment transverse myelitis with evidence of dissemination in space. Anti Aquaporin 4 immunoglobulin (AQP4IG-G) is an antibody directed against Aquaporin 4 channels in the Central Nervous System and is a highly sensitive and specific antibody for diagnosis of NMOSD. Recent criteria for diagnosis of NMOSD have liberalized the inclusion of serum aquaporin 4 seronegative patients based on other Clinical and Radiological criteria, which have led to increased diagnosis and treatment of these spectrum of patients. Typically, the relapses in NMOSD tend to be more severe and debilitating than MS often leading to incomplete or partial recovery. Immunomodulatory treatments can change the disease course significantly and prevent disability and mortality. It is very important to promptly diagnose these patients and start them on specific therapy.

**Conflict Of Interest:** None.

#### REFERENCES:

- Merritt's neurology, fourteenth Edition.
- Harrison's principles of internal medicine, 23rd Edition.
- Weinshenker BG, O'Brien PC, Peterson TM, et al. A randomized trial of plasma exchange in acute central nervous system inflammatory demyelinating disease. *Ann Neurol*. 1999;46:878-886.
- Chen H, Qiu W, Zhang Q, et al. Comparisons of the efficacy and tolerability of mycophenolate mofetil and azathioprine as treatments for neuromyelitis optica and neuromyelitis optica spectrum disorder. *Eur J Neurol*. 2017;24(1):219-226.
- Flanagan EP. Neuromyelitis optica spectrum disorder and other non-multiple sclerosis central nervous system inflammatory diseases. *Continuum (Minneapolis, Minn)*. 2019;25(3):815-844.
- Flanagan EP, Cabre P, Weinshenker BG, et al. Epidemiology of aquaporin-4 autoimmunity and neuromyelitis optica spectrum. *Ann Neurol*. 2016;79(5):775-783.
- Jarius S, Ruprecht K, Wildemann B, et al. Contrasting disease patterns in seropositive and seronegative neuromyelitis optica: a multicentre study of 175 patients. *J Neuroinflammation*. 2012;9:14.
- Lucchinetti CF, Mandler RN, McGavern D, et al. A role for humoral mechanisms in the pathogenesis of Devic's neuromyelitis optica. *Brain*. 2002;125(pt 7):1450-1461.
- Trebst C, Jarius S, Berthele A, et al. Update on the diagnosis and treatment of neuromyelitis optica: recommendations of the Neuromyelitis Optica Study Group (NEMOS). *J Neurol*. 2014;261(1):1-16.
- Wingerchuk DM, Banwell B, Bennett JL, et al. International consensus diagnostic criteria for neuromyelitis optica spectrum disorders. *Neurology*. 2015;85:177-189.