



MEDIAL OPENING WEDGE HIGH TIBIAL OSTEOTOMY FOR THE TREATMENT OF MEDIAL UNICOMPARTMENTAL KNEE OSTEOARTHRITIS

Dr. Pallav Seth	Postgraduate Resident, Department of Orthopaedics, SRGH, Jhalawar.
Dr. Karan Singh	Postgraduate Resident, Department of Orthopaedics, SRGH, Jhalawar.
Dr. Shiv Bhagwan Sharma	Senior Professor & Unit Head, Department of Orthopaedics, SRGH, Jhalawar.
Dr. Rajan Singh*	Postgraduate Resident, Department of Orthopaedics, SRGH, Jhalawar. *Corresponding Author

ABSTRACT

Medial unicompartmental knee osteoarthritis is a common condition that is frequently associated with significant pain and dysfunction. Medial opening wedge high tibial osteotomy (MOWHTO) offers a unique opportunity to preserve the knee joint and potentially alter the course of the degenerative process. Recent advances in this field of surgery have enabled surgeons to perform a MOWHTO in a safe, reliable and reproducible manner. Proximal/high tibial osteotomy (HTO) is a preferred strategy for clinically symptomatic osteoarthritis (OA) with genu varum due to painful medial compartment OA which is not amenable to conservative measures. To evaluate the outcomes of medial open-wedge HTO along with autologous bone grafting and buttress plate for the treatment of genu varum due to OA of the knee.

KEYWORDS : Knee, Osteoarthritis, Medial Opening-Wedge High Tibial Osteotomy, Unicompartmental Knee Osteoarthritis

INTRODUCTION

Osteoarthritis (OA) of the knee is common, with a worldwide prevalence estimated to be 22.9 % in those over the age of 40 yrs old [1]. Medial compartment OA is the most frequent pattern of tibiofemoral OA seen and it arises in isolation or in combination with patellofemoral joint OA in up to 27 % and 23 % of cases respectively [2]. Reliable surgical interventions for established OA of the knee are limited to joint replacement and re-alignment procedures in the form of osteotomy. The latter offers a unique opportunity to preserve the knee joint and potentially alter the course of the degenerative process.

Osteotomy surgery to treat unicompartmental knee OA (UKOA) is not a new concept. Through his work at the Mayo Clinic, Coventry popularized a lateral-closing wedge high tibial osteotomy to treat severe degenerative disease of the medial compartment [3]. The objective was to transfer the load away from the compartment that was failing and shift it towards the compartment that had little or no pathology. Securing his closing wedge osteotomy with a staple, he achieved good outcomes with 75 % survival at 10 yrs [4] and the procedure was widely adopted. However, its popularity was short-lived, and the subsequent success of arthroplasty surgery led to the role of osteotomy becoming less well-defined, and its widespread use steadily declined [5,6].

The modern era of orthopaedics has seen a dramatic evolution in almost every facet of osteotomy surgery. A medial opening wedge high tibial osteotomy (MOWHTO) secured with a low profile high tensile strength plate can be used to achieve an accurate correction with high rates of union and reliable outcomes [7]. It is no longer a niche procedure confined to specialist centres but a viable treatment option with reproducible results.

Deformity Analysis

To plan the required osteotomy correction, surgeons should be familiar with the mechanical axes of the lower limb and the principles of deformity correction described by Paley [8]. The weight-bearing axis (WBA) of the lower limb can be determined by drawing a straight line, termed the Miculicz line, from the centre of the femoral head to the centre of the ankle. In broad terms, if this line passes through the medial compartment, then the limb is confirmed to be in varus and the patient is a potential candidate for MOWHTO. The point at which the WBA crosses the tibial plateau can be expressed as

a percentage of the medial to lateral tibial plateau width. In medial uni compartment OA the varus deformity can relate to one of three different phenotypes which vary in severity based on the inherent tibiofemoral anatomy and associated soft tissue laxity [9].

1. *Primary varus:* Correlates with constitutional varus deformity in addition to any intra-articular varus caused by loss of medial joint space
2. *Double varus:* Separation of the lateral joint space due to attenuation of lateral soft-tissue restraints in addition to primary varus
3. *Triple varus:* Chronic excessive tensile forces in the posterolateral ligament structures, or traumatic injury leading to a varus recurvatum deformity in addition to double and primary varus

Tibiofemoral geometry is best assessed by means of a bilateral LLR. The mechanical axis of the femur is denoted by a line from the centre of the femoral head to the centre of the knee and the mechanical axis of the tibia relates to a line connecting the centre of the knee to the centre of the ankle. Using these mechanical axes, the medial proximal tibial angle (MPTA), mechanical Lateral Distal Femoral Angle (mLDFA), mechanical Lateral Proximal Femoral Angle (mLPFA) and mechanical Lateral Distal Tibial Angle (mLDTA) can be calculated (Fig. 1). The site of deformity is identified by establishing which of these alignment variables falls outside the expected physiological range (85–90)[8].

It is possible for surgical planning to reveal a patient with marked varus deformity and mechanical axis that are within normal physiological limits. As previously discussed, constitutional varus deformity is primarily determined by alignment of the proximal tibia and distal femur [10]; however, in the presence of medial compartment OA, intra-articular varus deformity will also contribute and so too may lateral ligament insufficiency. Joint Line Congruence Angle (JLCA) (normally considered to be less than or equal to 2) will indicate either the presence of an intra-articular deformity caused by either medial compartment cartilage loss and/or increased lateral soft tissue laxity.

It is critical that lateral joint space opening is recognized prior to surgery. As the lateral joint space opening will be reduced following the osteotomy, failure to recognize its presence will potentially lead to a significant over-correction [11]. Lateral

joint space opening of more than 5 mm on a weight-bearing long leg radiograph should be recognized as contributing to a severe varus deformity and accounted for [12]. A simple method to account for this is to measure the difference in lateral joint space width compared to the contralateral limb and subtract this from your calculated opening gap measurement.

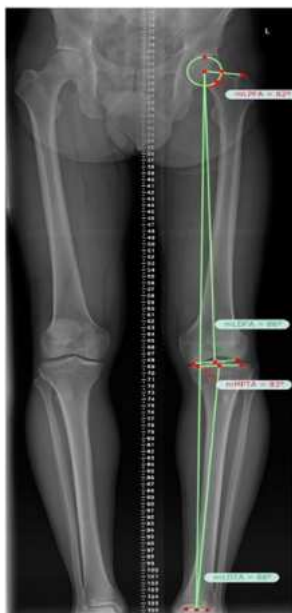

Fig. 1. A long leg radiograph of the left leg. A true AP projection of the tibiofemoral joint has been achieved. The Miculicz line from the centre of the femoral head to the centre of the ankle is shown. Measurement variables in the coronal plane are shown; mLPGA, mL DFA, mMPTA, mLDTA. Measurements obtained using TraumaCad®(Brainlab, Westchester, USA).

MATERIALS AND METHODS

1) Advantages And Disadvantages

Medial opening wedge osteotomy is a relatively simple procedure that involves a single osteotomy and a few dissections. The technique does not necessitate either a fibular osteotomy that has been associated with neurovascular complications or bone resection of the lateral tibia. Accordingly, the normal anatomical tibial bone shape is maintained after the procedure, which allows for conversion to knee replacement. The level of correction can be identified and adjusted intraoperatively on the coronal and sagittal planes and shortening of the lower limbs can be prevented or treated.

However, the technique has been associated with high nonunion rates, long period of weight-bearing restriction, and leg lengthening. Other disadvantages include harvest site morbidity, loss of correction due to unstable fixation, and increase in posterior tibial slope due to anterior position of the metal plate.

2) Good candidates for medial opening wedge osteotomy.

Medial opening wedge osteotomy can be more effective than closing wedge HTO in knees with ≥ 2 mm leg length discrepancy, a combined posterior cruciate ligament injury, patella alta, or medial collateral ligament laxity.

3) Surgical technique

The patient is placed in the supine position on a radiolucent operating table and a tourniquet is applied. An arthroscopy can be used at the same time to diagnose and treat intraarticular lesions. A 5-cm vertical incision is made over the center between the medial aspect of the tibial tuberosity and the posteromedial aspect of the tibia below the joint line. The

pes anserinus is detached from the tibia to expose the superficial medial collateral ligament. The distal portion of the exposed ligament is separated from bone and a blunt retractor is inserted posterior to the medial collateral ligament and the tibia to protect the neurovascular structures posterior to the incision line. After identifying the medial border of the patellar tendon, subperiosteal dissection is performed from the tibial tuberosity to the posteromedial aspect of the tibia. Two guide wires are inserted at a point 3.5-4 cm below the medial joint line and passed obliquely 1 cm below the lateral articular margin of the tibia towards the tip of the fibular head (Fig. 2A). After checking the appropriate location with fluoroscope, a tibial osteotomy is performed immediately below the guide wires using an oscillating saw or an osteotome (Fig. 2B). Ensure the osteotomy line extends from the tibial tuberosity along the posteromedial aspect of the tibia to 1 cm medial to the lateral tibial cortex and is in parallel with the posterior tibial slope on the sagittal plane. The mobility of the osteotomy site is checked and the osteotomy is opened with a valgus force. If the opening of the osteotomy seems insufficient, use 2 or 3 stacked osteotomes to reduce the risk of intraarticular fractures.

Subsequently, a calibrated wedge is inserted until the osteotomy is opened to the desired extent (Fig. 2C).

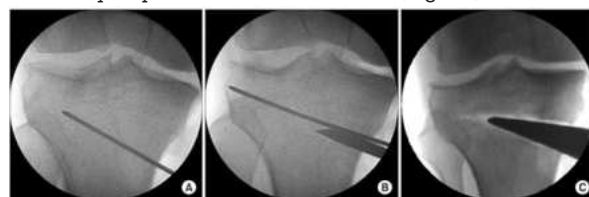


Fig. 2. Opening wedge osteotomy. (A) A guide wire is placed from 3.5-4 cm below the medial joint line to about 1 cm below the lateral articular margin of the tibia. (B) Cortical osteotomy is performed with an oscillating saw inferior to the guide wire and an osteotome. (C) When the osteotomy is completed, the medial tibia is opened with a wedge.

Ensure with fluoroscopy when a long alignment rod or wire cable is centered over the hip joint and the ankle joint it lies at 62.5% of the width of the tibial plateau . Once the desired degree of correction is achieved, internal fixation of a metal plate is performed. There are various types of metal plates including the Puddu plate, Tomofix, Aesculap (dual) plate, - plates with or without a spacer (rectangular or tapered). Among these, spacer plates are most commonly used and the metal block should be identical to the calibrated wedge. The proximal fixation screws should be used under fluoroscopic guidance and the defect should be grafted using iliac crest autograft, allograft, or a bone substitute. For defects ≥ 10 mm, corticocancellous autografts or allografts are used, whereas for small defects, bone grafting is optional.

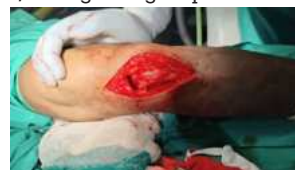

Figure 3. Intra Operative Image

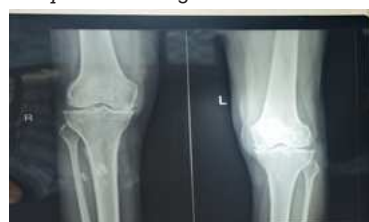

Figure 4. PRE -OP X-RAY Bilateral medial compartment osteoarthritis

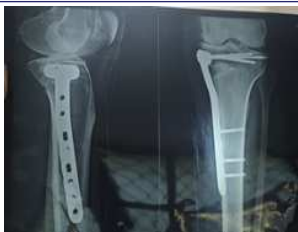

Figure 5. Immediate POST-OP X-RAY

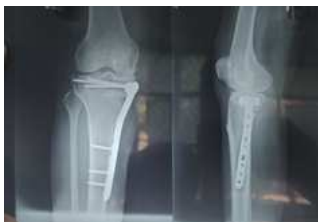

Figure 6. POST-OP X-RAY AFTER 2 MONTHS

OBSERVATION AND RESULTS

The following observations were made from the data collected during this study of total 10 knees of medial compartment osteoarthritis treated by medial open wedge osteotomy. In our study criteria of results are Mechanical axis should pass through Fujisawa point. Union of osteotomy (radiologically) Holding of osteotomy with implant. Able to squat and sit cross leg.

To study the age distribution, all the patients included in our study were divided into groups with 10 years interval. In our study the major group of patients belong to 41-50 yrs (40%). The mean age of patients of our study is 51.2 years.

In our study there was significant improvement of Knee Clinical Score and Knee Functional Score following medial open wedge osteotomy with bone grafting.

In our study of medial open wedge osteotomy for medial compartment osteoarthritis the average knee clinical score preoperatively was 56.32 and the average post-operative clinical score was 94.52. The average knee functional score was 72.21 preoperatively which increased to average score of 92.32. The majority of patients reported alleviation of pain at six months of follow-up.

In our study we got clinical union by 2-4 months of time. The mean time of clinical union is 2.5 months. In our study we got radiological union by 3-5 months of time. The mean time of radiological union is 3.65 months. In our study average flexion is 120.86 degrees.

In the operated group there were two complications that occurred during the period of the study. One patient had superficial wound infection that promptly responded to antibiotic therapy and dressing. One case was having intra-articular extension of osteotomy which was united by the time of 5 months and these patients were having good range of knee motion at the final follow-up.

CONCLUSION

HTO is a procedure performed to treat medial knee arthritis in young or middle-aged active patients. Appropriate patient selection, proper osteotomy types, and precise surgical techniques are essential to the success of HTO. Drawbacks of the procedure are restricted motion during the bone union period and possibility of delayed union or nonunion. On the other hand, participation in aggressive activities is allowed after bone union and the reported short-term follow-up clinical results are excellent in 80-90% of the patients. In addition, the successful outcome of HTO can be maintained for more than 8 to 10 years, delaying the need for conversion to TKA. Therefore,

I think HTO should be recommended for the treatment of degenerative arthritis of the knee in young, active patients for symptomatic improvement and maintenance of activity levels.

Acknowledgment

REFERENCES

- [1] Cui A, Li H, Wang D, Zhong J, Chen Y, Lu H. Global, regional prevalence, incidence and risk factors of knee osteoarthritis in population-based studies. *EClinicalMedicine* 2020;29-30:100587
- [2] Stoddart JC, Dandridge O, Garner A, Cobb J, van Arkel RJ. The compartmental distribution of knee osteoarthritis—a systematic review and meta-analysis. *Osteoarthritis Cartilage* 2021;29:445–55.
- [3] Coventry M. Osteotomy of the upper portion of the tibia for degenerative arthritis of the knee. A preliminary report. *J Bone Joint Surg Am* 1965;47:984–90. PMID: 14318636.
- [4] Coventry MB, Ilstrup D, Wallrichs S. Proximal tibial osteotomy. A critical long-term study of eighty-seven cases. *J Bone Joint Surg Am* 1993;75:196–201.
- [5] W-Dahl A, Robertsson O, Lidgren L. Surgery for knee osteoarthritis in younger patients: a Swedish register study. *Acta Orthop* 2010;81:161–4.
- [6] Niinimäki TT, Eskelinen A, Ohtonen P, Junnila M, Leppilähti J. Incidence of osteotomies around the knee for the treatment of knee osteoarthritis: a 22-year population-based study. *Int Orthop* 2012;36:1399–402.
- [7] Lobenhoffer P, Agneskirchner JD. Improvements in surgical technique of valgus high tibial osteotomy. *Knee Surg Sports Traumatol Arthrosc* 2003;11:132–8.
- [8] Noyes FR, Barber-Westin SD, Hewett TE. High tibial osteotomy and ligament reconstruction for varus angulated anterior cruciate ligament-deficient knees. *Am J Sports Med* 2000;28:282–96.
- [9] Dugdale TW, Noyes FR, Styer D. Preoperative planning for high tibial osteotomy. The effect of lateral tibiofemoral separation and tibiofemoral length. *Clin Orthop Relat Res* 1992;248–64. PMID: 1729010.
- [10] Bellemans J, Colyn W, Vandenneucker H, Victor J. The Chitranjan Ranawat award: is neutral mechanical alignment normal for all patients? The concept of constitutional varus. *Clin Orthop Relat Res* 2012;470:45–53.
- [11] Colyn W, Cleymans A, Bruckers L, Houben R, Smeets K, Bellemans J. The lateral joint line opening: a radiographic indicative parameter for high grade varus knees. *J Exp Orthop* 2022;9:4–9.
- [12] Feucht MJ, Winkler PW, Mehl J, Bode G, Forkel P, Imhoff AB, et al. Isolated high tibial osteotomy is appropriate in less than two-thirds of varus knees if excessive overcorrection of the medial proximal tibial angle should be avoided. *Knee Surg Sports Traumatol Arthrosc* 2021;29:3299–309.