



## A PROSPECTIVE STUDY OF COLLAGEN TYMPANOPLASTY IN CHRONIC SUPPURATIVE OTITIS MEDIA

**Dr. K. Jayasudha\***

Assistant professor ENT. \*Corresponding Author

**Dr. S. Ramesh Kumar**

Assistant professor ENT.

**Dr. Praveen. DV**

Associate professor Anaesthesiology.

### ABSTRACT

Chronic Suppurative Otitis media is the most common disease seen in daily ENT OPD basis. There are different types of methods to close the perforation of the tympanic membrane. Normally we were using older surgical method for the closure of the tympanic membrane. Recently there are different method of tympanoplasty used one such type becoming trending is collagen tympanoplasty. Collagen membrane is used to close the tympanic perforation. It is semi permeable barrier assisted electrophoretic deposition. In this study we have taken 50 patients of which 32 males and 18 females. After otoscopic examination and preop and postop audiometry assessment done. Then the patients underwent collagen tympanoplasty. After the procedure done patients were subjected to hearing test after 1 month and otoscopic examination. The patients had improved hearing and perforations were sealed. This type of procedure are scar less and minimally invasive.

### KEYWORDS :

#### INTRODUCTION

Chronic suppurative otitis media (CSOM) constitutes a major public health problem in adults (1, 2). It is characterized by ear discharge, decreased hearing, tinnitus, ear blocking sensation. This disease is the most common among childrens and adults worldwide, starting early in life (1). However, in the worldwide, risk factors such as malnutrition, over-crowding, substandard hygiene, frequent upper respiratory tract infections, and healthcare compound problems and make the disease prevalent among children and adults (1,3-6).

A Chronic otitis media (COM) is defined as a "chronic inflammation of the middle ear and mastoid cavity", with hearing loss and a persistent to recurrent ear infection and ear discharge (4-6). Adoga et al. (1) stated that all the complications associated with CSOM, hearing loss is nearly always significant. Prevalence of hearing loss in CSOM ranges from 9-83% have been reported (1,4,5).

Tympanic Membrane Perforation require surgical repair of the tympanic membrane (TM). In 17th to the 19th centuries, many techniques were used to close the tympanic membrane perforations. In 1887, the "paper patch" technique developed by Blake. In 1876, cauterizing agents like silver nitrate used by Rossa, over the rim of the perforation to induce healing of tympanic membrane perforations. In 1895, Joynt used 0.33% of Trichloroacetic acid was used for the first time for chemical cauterisation. [5]. In 1952, split-thickness skin graft for closing perforations by Wullstein [7]. Then, Zöllner described with a similar graft [8]. Wullstein and Zöllner introduced microscopic assisted tympanoplasty. In which significantly enhanced surgical results due to improved accuracy of the technique. Then the other graft materials, with Zollner describing fascia lata (1956), Heerman temporalis fascia (1958) and Shea vein grafts (1960). Since then the list of potential graft materials has expanded to include, cartilage, periosteum, perichondrium, fat, subcutaneous tissue, amniotic membrane, dermal matrix, fibro- blasts and sclera. Allograft are processed from human allograft skin and it rendered immunologically inert, can provide an alternative to temporalis fascia when is not available, with a success rate of 87.5%, equivalent to that of temporalis fascia [9]. Basic fibroblast growth factor (FGF) has been used either in combination with atelocollagen, a type 1 collagen material are derived from calf dermis, with closure achieved in 92% [10]. than the traumatic perforations used via a Gelfoam patch over the perforation done by Lou Z [11].

Collagen sheets are available in the market. As a Sterile Biological material containing Collagen Sheet (Collrez, India) preserved in Isopropyl Alcohol. It is semipermeable barrier assisted electrophoretic deposition. It is a semi transparent, self-adhesive flexible material. It helps in the formation of granulation tissue, blood vessels and the re-epithelization [12, 13]. This study is conducted to scientifically determine effectiveness and improvements achieved by Collagen Sheets as a graft in tympanoplasty in terms of graft uptake and hearing gain in patients with small to medium perforation.

#### MATERIALS AND METHODS

This is a prospective study done after ethical clearance. Detailed Informed Consent was taken from all the 50 Participants who have visited ENT opd from june2022 to may 2024 explaining the procedure, risks and benefits about the procedure. Patients were selected from ENT OPD with complaints of ear discharge, tinnitus and hearing loss were examined in detail and those patients having small or moderate central perforation with mucosal type of chronic otitis media and with pure conductive hearing loss of less than 35 db air bone gap and age more than 18 years with a pneumatized mastoid air cells on Xray Schuller's view with dry type of ear for more than 4 weeks were included in this study. Patients with active ear discharge were subjected to appropriate antibiotics to maintain dry state for at least 1 month were taken in this study.

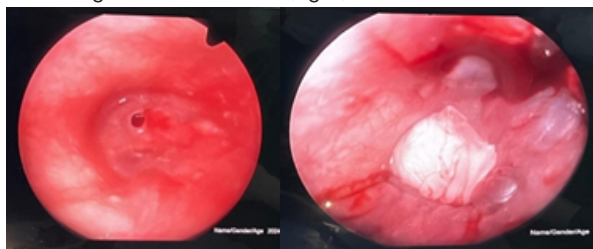
Detailed history taken and clinical examination of ear, nose and throat was carried out and were recorded. Oto-endoscopic examination was done in all the cases with 0 degree to record the perforation size, location, status of the middle ear mucosa.

Pure tone audiogram was done in all the study patients, with the help of an Audiometer having standard calibration of Air Conduction (AC) threshold and Bone Conduction (BC) thresholds were recorded in all the patients who were considered for the study to assess the degree and type of hearing loss. Pure tone Audiometry was performed pre operatively and 3 months after procedure to assess the degree of the hearing. The pre-operative audiogram was compared with post-operative audiogram (after 3 months) to know the hearing improvement.

The procedure was performed under local infiltration with or

without any sedation or General Anaesthesia. Under aseptic precaution using 0 degree endoscope with HD endoscopic guidance, was carried out as follows:

- The external auditory canal (EAC) was cleaned with betadine solution and along with the TM, locally anesthetized using a 2% lidocaine infiltration in EAC.
- Entire procedure was performed under endoscope through trans-canal route (fig: 1).



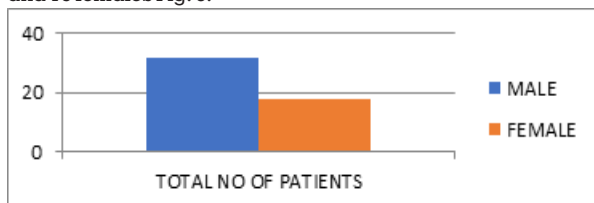
**Figure: 1** perforation seen in Antero inferior quadrant.

**Figure: 2** Collagen placed insitu.

- Collagen sheet was cleaned thoroughly with normal saline.
- The collagen sheet was divided according to the different size of the perforation.
- The TM was inspected, and the edge of the perforation was unfolded using a curved needle and margin of the perforation was freshened and under surface of the TM was scrapped with Rosen knife.
- Pieces of absorbable Gel foam were kept inside the Middle ear to make bed for collagen pieces [11, 12] (Fig. 2).
- The lateral side of TM was covered with a second collagen sheet.
- A few absorbable gel-foam fragments were kept lateral to the collagen.

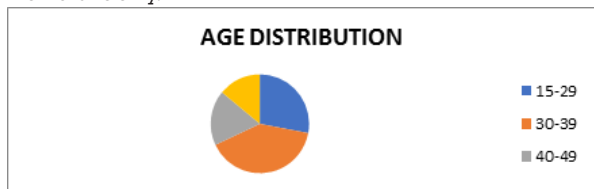
**RESULTS**

In this study we have taken 50 patients, out of which 32 males and 18 females Fig: 3.



**Figure: 3** Total no of patients taken in study according to sex ratio

Here the patients age ranges between 15 to 60 years are included in this study. Maximum numbers of patients are between 30 to 40 years age group Fig:4. Etiologies of the perforations mainly due to traumatic and inflammatory conditions are taken in this study. Most of the patients had small perforation involving one quadrant of tympanic membrane only.



**Figure: 4** Age distribution taken in the study population.

All the patients underwent thorough ear, nose, and throat examination. Otoscopic examination was done under 0 degree endoscope and the results are recorded. Pre-op and post-operative air-bone gap has been recorded for all the patients. Out of 50 patients, 46 patients had overall success rate and the remaining four patients had residual perforation.

The 46 patients who had undergone collagen tympanoplasty had pre-operative air-bone gap range between 26 to 35 decibel with average air-bone gap of 28.5 db. The post-operative air-bone gap range between 18 to 25 decibel with average of 20.6 decibels Fig: 5.

AUDIOLOGY FREQUENCY	Total no of PRE OP audiology frequency	Total no of POST OP audiology frequency
15db-20db	-	30
21db-30db	40	10
31db-35db	10	-

**Figure: 5** Comparison of Pre op and Post op audiology frequency.

The average hearing improvement in the collagen tympanoplasty was 7.9 decibel. The remaining four patients had undergone endoscopic tympanoplasty by underlay technique using cartilage and temporalis fascia and was successful.

**DISCUSSION**

There are various methods of tympanoplasty present of which recently collagen tympanoplasty is the recent method for the closure of perforation in chronic otitis media patients. They are minimally invasive, less discomfort, fast healing with significant hearing improvement. A large amount of collagen fibrils are present in the fibrous layer of tympanic membrane [13]. The collagen sheet composed of same physical features of the pars tensa of the tympanic membrane. Histopathologically, proliferation of squamous epithelium seen at the edge of the perforation within 12 hours, granulation formation seen within 18 hours while the inner mucosal layer takes several days to regenerate. The main action of collagen sheet in the perforation is to provide collagen for new tissue formation over the fibrous layer acting as a bridge between the margins of perforation [14].

During the acute healing phase, more collagen is present after trauma and infection. During the inflammatory and healing stages, collagen content of the tympanic membrane is modified. The modified collagen content of the healing and inflammatory stage is restored by the collagen sheet over the fibrous layer of the tympanic membrane.

The main advantages of collagen sheet are its easy availability, easy storage and easy to use. It can be done under IV sedation using endoscopic method. By doing the surgery in hypotensive anaesthesia it reduces blood loss with good field of surgery. Most importantly the main advantage by using collagen was fast healing with less post operative complication.

**CONCLUSION**

The recent trend of using collagen is the most effective method for the closure of tympanic membrane with small perforations. Collagen tympanoplasty has significant improvement in hearing post-operatively. Closure of perforation by using collagen sheet is easy, cost-effective, cosmetically better and fast healing, avoids hospitalisation for long period of time.

**REFERENCES**

1. Adoga A, Nimkur T, Silas O. Chronic suppurative otitis media: Socio-economic implications in a tertiary hospital in Northern Nigeria. *Pan Afr Med J.* 2010;4(3) [PMC free article] [PubMed] [Google Scholar]
2. Acuin JM. Chronic suppurative otitis media: a disease waiting for solutions. *Comm Ear Hearing H.* 2007;4(6):17-19. [Google Scholar]
3. Olusesi AD, Opaluwah E, Hassan SB. Subjective and objective outcomes of tympanoplasty surgery at National Hospital Abuja, Nigeria 2005-2009. *Eur Arch Otolaryngol.* 2011;268(3):367-72. [PubMed] [Google Scholar]
4. Lasisi AO, Sulaiman OA, Afolabi OA. Socio-economic status and hearing loss in chronic suppurative otitis media in Nigeria. *Ann Trop Paediatr.* 2007;27(4):291-6. [PubMed] [Google Scholar]
5. Akinpelu OV, Amusa YB, Komolafe EO, Adeolu AA, Oladele AO, Ameye SA. Challenges in management of chronic suppurative otitis media in a developing country. *J Laryngol Otol.* 2008;122(1):16-20. [PubMed] [Google Scholar]

6. Joynt JA. Repair of drum. *IowaMedSoc*. 1919;9:51. [Google Scholar]
7. Wüllstein H. Funktionelle Operationen im Mittelohr mit Hilfe des freien Spaltlappen-Transplantates. *Arch Ohren-Nasen- u Kehlkopfh*. 1952;161:422. doi: 10.1007/BF02129204. [CrossRef] [Google Scholar]
8. Zollner F. The principles of plastic surgery of the sound-conducting apparatus. *J LaryngolOtol*. 1955;69:637. doi: 10.1017/S0022215100051240. [PubMed] [CrossRef] [Google Scholar]
9. Fayad JN, Bairo T, Parisier SC. Preliminary results with the use of AlloDerm in chronic otitis media. *Laryngoscope*. 2003;113(7):1228-1230. doi: 10.1097/00005537-200307000-00022. [PubMed] [CrossRef] [Google Scholar]
10. Hakuba N, Iwanaga M, Tanaka S, et al. Basic fibroblast growth factor combined with atelocollagen for closing chronic tympanic membrane perforations in 87 patients. *OtolNeurotol*. 2010;31(1):118-121. [PubMed] [Google Scholar]
11. Lou Z. Healing large traumatic eardrum perforations in humans using fibroblast growth factor applied directly or via gel-foam. *OtolNeurotol*. 2012;33(9):1553-1557. [PubMed] [Google Scholar]
12. Lim DJ. Structure and function of the tympanic membrane: a review. *Acta Otorhinolaryngol Belg*. 1995;49:101-115. [PubMed] [Google Scholar]
13. Glasscock ME, Gulya AJ. *Glasscock-Shambaugh Surgery of the Ear*. 5. Hamilton: BC Decker Inc.; 2003. pp. 400-420. [Google Scholar]
14. Stenfeldt K, Johansson C, Hellström S. The collagen structure of the tympanic membrane: collagen types I, II, and III in the healthy tympanic membrane, during healing of a perforation, and during infection. *Arch Otolaryngol Head Neck Surg*. 2006;132:293-298. doi: 10.1001/archotol.132.3.293. [PubMed] [CrossRef] [Google Scholar]